



3 1761 06704967 6



Ex  Libris
Oskar Klotz



Digitized by the Internet Archive
in 2007 with funding from
Microsoft Corporation

DESCRIPTIVE CATALOGUE
OF THE
MEDICAL MUSEUM
OF
MCGILL UNIVERSITY

OXFORD UNIVERSITY PRESS

HUMPHREY MILFORD M.A.

PUBLISHER TO THE UNIVERSITY

MP
M

Mc Gill University. Medical Museum

DESCRIPTIVE CATALOGUE
OF THE
MEDICAL MUSEUM
OF
McGILL UNIVERSITY

ARRANGED ON A MODIFIED DECIMAL SYSTEM
OF MUSEUM CLASSIFICATION

AND EDITED BY
MAUDE E. ABBOTT, B.A., M.D., CURATOR

PART IV: SECTION I

THE HÆMPOIETIC ORGANS

CATALOGUE AND DIDACTIC INTRODUCTIONS

BY
OSKAR C. GRUNER, M.D.

PATHOLOGIST TO THE ROYAL VICTORIA HOSPITAL, MONTREAL
ASSISTANT PROFESSOR OF PATHOLOGY, MCGILL UNIVERSITY



359102
30. 12. 38.

OXFORD
AT THE CLARENDON PRESS
1915




TABLE OF CONTENTS

	PAGE
PREFACE	ix
CLASSIFICATION	xiii
CATALOGUE	1
41 BONE-MARROW :	
Introduction	3
Detailed Contents of Section	6
Catalogue	8
42 LYMPH-NODES :	
Introduction	27
Detailed Contents of Section	32
Catalogue	34
43 SPLEEN :	
Introduction	69
Detailed Contents of Section	76
Catalogue	81
44 THYMUS GLAND :	
Introduction	187
Detailed Contents of Section	189
Catalogue	190

LIST OF PLATES

PLATE		FACING PAGE
I.	41 ¹ BONE-MARROW OF AN INFANT FROM TRANSVERSE SECTION OF NORMAL STERNUM. Hæm. & Eryth. Zeiss imm. oc. 6. Presented by Dr. Gruner .	8
II.	41.711 ¹ BONE-MARROW OF A YOUNG ADULT SHOWING ERYTHROBLASTIC AND LEUCOBLASTIC REACTION. From case of Malignant Endocarditis. Triacid Stain. Zeiss imm. oc. 12. Presented by Dr. Gruner .	16
III.	41.711 ⁴ BONE-MARROW SHOWING LEUCOBLASTIC REACTION. From a case of Puerperal Fever. Jenner Stain. Zeiss imm. oc. 12. Presented by Dr. Gruner .	17
IV.	42.361 ¹⁵ TUBERCULOSIS OF MESENTERIC LYMPH-NODES IN MONKEY. Dr. Duval	41
V.	42.514 ¹ LYMPH-NODES IN LYMPHATIC LEUKÆMIA. Dr. Wolbach	43
VI.	VARIATIONS IN SIZE OF SPLEEN IN DIFFERENT CONDITIONS .	81
VII.	43.17 ³ ACCESSORY SPLEEN, ATTACHED TO ORGAN OF NORMAL SIZE	82
VIII.	43.26 ⁹⁰ OLD INFARCT IN CARDIAC SPLEEN. } Dr. C. F. Martin	92
IX.	43.325 ³ SEPTIC INFARCT, ABSCESS IN SPLEEN, OF MALIGNANT ENDOCARDITIS. Dr. Fraser Gurd	101
X.	43.361 ¹ SUBACUTE MILLIARY TUBERCULOSIS OF SPLEEN. Dr. Adami	117
XI.	43.513 ¹ SPLEEN FROM BANTI'S DISEASE, PRIMARY SPLENO-MEGALY, WITH CIRRHOSIS HEPATIS. HYALOSEROSITIS OF CAPSULE. Dr. Wolbach	129
XII.	43.513 ³ SPLEEN IN BANTI'S DISEASE. HYALOSEROSITIS. Dr. Gruner	130

TO THE MEMORY OF
WYATT GALT JOHNSTON



PREFACE

THE present volume of the *Descriptive Catalogue of the Medical Museum of McGill University*, although the fourth in the order of the Museum classification, is the first portion ready for publication. We owe its timely appearance to the activity of Professor Gruner, who, as collaborator on this section, has catalogued the specimens, written the didactic introductions, and appended a detailed table of contents in catalogue numbers. The specimens have also been examined microscopically wherever this was of interest, and the corresponding slides filed in the Museum, where they are readily accessible to the student. This feature is of especial importance in the present series on the hæmopoietic organs, both because the gross appearances are here frequently insufficient for diagnosis, and because the pathogenesis of these conditions is in many cases still obscure.

A word of explanation on the system of cataloguing as applied in this Museum is necessary.

The Museum Classification. The specimens are arranged on a system of Museum classification after a plan suggested by the late Professor Wyatt Johnston, and introduced in the year 1899. A descriptive number is used, in which the number representing the anatomical condition precedes, and that representing the pathological follows the decimal point, the individual specimen being indicated by a small index figure placed to the right of, and above, the descriptive number. The advantage of this system is that it allows of indefinite expansion, the catalogue number becoming

the shelf number and each descriptive number forming a unit group to which specimens may be added at will without disturbing the logical sequence of the collection as a whole. A further subdivision of specimens in a given group is also followed in some cases by leaving a gap in the small index figures of five or ten numbers: thus 42.361¹⁻¹¹ are specimens of human tuberculosis of the lymph-glands; 42.361¹⁵⁻¹⁹ tuberculosis of glands in a monkey; 42.361²⁰⁻³⁰ bovine tuberculosis of lymphatic glands, &c.

The classification is published in this volume in a slightly abridged form. It will appear in full in Part I of the Catalogue, which volume is not yet ready for the press.

Expert Collaboration. The Catalogue of this Museum is being carried out on a more detailed and scientific scale than would otherwise be possible, through the collaboration of various members of the Teaching Staff engaged in clinical or pathological research, who have undertaken to work over the material on a given subject in the light of their expert knowledge. The ideal aimed at has been the formation of a Museum collection consisting of good specimens carefully studied and described, with clinical histories and microscopic findings attached, and arranged in teaching series. The collaborator's work consists in completing the particular series under his care by the selection of representative material from storage, indicating lacunæ to be supplied from the hospitals or elsewhere, examining and cataloguing the specimens, and writing a short didactic introduction upon them, the whole being done with the assistance and active co-operation of the Museum Staff, and subject to the revision of the Professor of Pathology. In this connexion the attention of the student is directed to page 30, where, under the Introduction to the Section

on Lymph-nodes, an elucidation of our present knowledge on the leukæmias and allied states is added by Professor Adami.

The plan of cataloguing in collaboration with clinical workers is not original, but is carried out in several of the English museums, notably that of University College, London, where it has been in practice for a number of years. In extent and thoroughness, however, the proceeding is, we think, unique here. It is hoped that the fine illustrative series presented in this, the first fasciculus issued, as well as its general construction, will justify the conception it embodies, and encourage the successful continuance of the Catalogue along similar lines.

The *Descriptive Catalogue of the Museum of McGill University* has become the peculiar property of the Medical Graduates by the practical action of one whose early connexion with the School forms one of its chief distinctions, and whose personality is the object of its warmest affection. It is our privilege to acknowledge that the expenditure incurred in the publication of this volume is covered by a fund raised for this purpose among the Graduates in Medicine by the Regius Professor of Medicine at Oxford University, Sir William Osler, Bart., at whose instance also it is now issued. In a circular sent out by Sir William in 1905 the attention of Graduates was drawn to the wealth of material in the Museum and to the importance which a careful catalogue would have in preserving the historic traditions of the Medical School, as well as in developing its scientific and teaching capacity. The response to this appeal was immediate, the \$1,200.00 requested being subscribed within a few weeks. The fire of 1907 interrupted the work, and has

led ultimately to the substitution of this volume for the one originally intended to be first published, that on the Circulatory System, which is still in course of preparation.

The initiative taken by Sir William Osler in this matter, and the generosity of the spirit in which it was met, form an inspiration and supply a stimulus that will, we hope, continue to be reflected in later volumes, until the extensive task of cataloguing the Museum is complete.

MAUDE E. ABBOTT.

March 2, 1914

KEY TO THE CLASSIFICATION

IN USE IN THE MEDICAL MUSEUM, MCGILL UNIVERSITY,
MONTREAL

DEPARTMENT OF SPECIAL PATHOLOGY

Note.—The anatomical condition is represented by numbers before and the pathological conditions by numbers after the decimal point. The number of the individual specimen is represented by a small index figure placed to the right of the catalogue number, e.g. 43.26¹ Infarction of the Spleen. A further subdivision of specimens is followed in some cases, by leaving a gap in the small index figures of five or ten numbers: thus 42.361¹⁻¹¹ are specimens of *human* tuberculosis of lymph-glands; 42.361¹⁵⁻¹⁹ tuberculosis of glands in a *monkey*; 42.361²⁰⁻³⁰ *bovine* tuberculosis of lymph-glands.*

PART I. ANATOMICAL CLASSIFICATION

1. CIRCULATORY SYSTEM.
 11. Pericardium.
 12. Myocardium.
 13. Endocardium.
 14. Heart as a whole.
 15. Arteries.
 16. Veins.
2. RESPIRATORY SYSTEM.
 21. Nares.
 22. Larynx.
 23. Trachea and Bronchi.
 24. Lungs.
 25. Pleura.
3. DIGESTIVE SYSTEM.
 31. Teeth.
 32. Mouth. Tongue. Pharynx.
 33. Oesophagus
 34. Stomach.
 35. Intestines.
 36. Peritoneum and Mesentery.
 37. Liver.
 38. Gall-bladder and Bile Ducts.
 39. Pancreas.

* For further explanation see 'On the Classification of Museum Specimens', *American Medicine*, 1903, p. 541.

4. HÆMOPOIETIC ORGANS AND DUCTLESS GLANDS.

41. Bone-marrow.
42. Lymph-nodes.
43. Spleen.
 431. Spleen capsule.
44. Thymus Gland.
45. Thyroid.
46. Parathyroids.
47. Adrenal.
48. Carotid and Coceygeal Glands.
49. Pituitary Body.

5. UROGENITAL SYSTEM.

51. Kidney.
52. Ureter.
53. Bladder.
54. Prostate.
55. Urethra.
56. Penis.
57. Seminal Vesicles, Vas Deferens, and Cord.
58. Testis, Epididymis, Tunica Vaginalis.
59. Perineum.

6. FEMALE GENITALIA.

61. External Genitalia.
62. Vagina.
63. Uterus.
64. Fallopian Tube.
65. Ovary and Parovarium.
66. Pelvic Peritoneum and Connective Tissue.
67. Breast.
68. Generative System in Pregnancy
69. Ovum as a whole.

7. NERVOUS SYSTEM.

71. Membranes.
72. Cerebral Vascular System.
73. Cerebrum.
74. Cerebellum.
75. Spinal Cord.
76. Nerves.
77. Nerve Ganglia.
78. Eye.
79. Ear.

8. MUSCULO-CUTANEOUS SYSTEM.

81. Skin.
82. Hair.
83. Nails.
84. Muscle.
85. Fascia.
86. Cellular Tissue.
87. Tendon.
88. Ligaments.
89. Bursæ.

9. OSSEOUS AND ARTICULAR SYSTEM.

91. Bones of Cranium.
92. Bones of Face.
93. Vertebrae.
94. Sternum.
95. Ribs.
96. Bones of Upper Extremity.
97. Pelvic Girdle.
98. Bones of Lower Extremity.

0. REGIONAL.

01. Head.
02. Face.
03. Neck.
04. Back.
05. Thorax.
06. Abdomen.
07. Pelvis.
08. Upper Extremity.
09. Lower Extremity.

PART II. PATHOLOGICAL CLASSIFICATION

.1 ANTENATAL STRUCTURES AND ABNORMALITIES OF DEVELOPMENT.

- .11 Fœtal Structures (Normal Anatomy).
- .12 Malformations of Incomplete Development.
- .13 Reduction in Size (Hypoplasia).
- .14 Reduction in Number (Syndactylism, &c.).
- .15 Persistent Fœtal Structures.
- .16 Excess in Size.
- .17 Excess in Number.
- .18 Malposition or Heterotaxis ; Aberrant Structures.
- .19 Anomalies due to Fœtal Disease.

.2 CIRCULATORY DISTURBANCES.

- .21 Anæmia.
- .22 Congestion or Hyperæmia.
- .23 Hæmorrhage.
- .24 Thrombosis.
- .25 Embolism.
- .26 Infarction.
- .27 Œdema.

.3 INFLAMMATORY PROCESSES.

- .31 Catarrhal or Desquamative.
- .32 Exudative.
 - .321 Sero-fibrinous Inflammation.
 - .322 Fibrinous or Plastic Inflammation.
 - .323 Diphtheritic or Membranous.
 - .324 Hæmorrhagic.
 - .325 Suppurative or Purulent (Abscess).
- .33 Destructive.
- .34 Specific Inflammations due to Cocci.
 - .341 Lesions due to Micrococci.
 - .342 Lesions due to Staphylococci.
 - .343 Lesions due to Streptococci.
 - .344 Lesions due to Pneumococci.
 - .345 Lesions due to Gonococci.
 - .346 Lesions due to Meningococcus.
- .35 Specific Inflammations due to Bacilli.
 - .351 Lesions due to Colon and Typhoid.
 - .352 Lesions due to Intermediate Forms of Intestinal Bacilli.
 - .353 Lesions due to Dysentery.
 - .354 Lesions due to Diphtheria.
 - .355 Lesions due to Eye Bacilli.
 - .356 Lesions due to Anaerobes.
 - .359 Lesions due to *B. Pestis* (Bubonic Plague).
- .36 Specific Inflammations due to Acid-fast Bacilli, Spirilla, and Yeasts and Moulds.
 - .361 Lesions due to *Bacillus Tuberculosis*.
 - .362 Lesions due to the *Bacillus Lepre*.
 - .363 Lesions due to Malignant Granuloma.
 - .364 Lesions due to the *Bacillus Mallei* (Glanders).
- .37 Specific Inflammations due to Protozoa.
 - .371 Lesions due to *Amœba Dysentericæ* (Tropical Dysentery).
 - .372 Lesions due to *Treponema Pallidum* (Syphilis).

- .373 Lesions due to *Trypanosoma Gambiense* (Sleeping Sickness).
- .374 Lesions due to *Spirochætes* (Sp. *Obermeieri*, Relapsing Fever; Sp. *Vincenti*, Vincent's Angina, &c.).
- .375 Lesions due to *Leishmania* (*L. Donovanii*, Kala-azar).
- .376 Lesions due to *Hæmosporidia* (Malaria).
- .38 Specific Inflammations, Causative Agents still undetermined.
- .39 Productive or Proliferative Processes.

.4 INFECTIONS AND PARASITES.

(*Note*.—As this section is used chiefly in the collections of bacteriology and parasitology, its subdivisions are not given here.)

- .41 Cocci.
- .42 Bacilli.
- .43 Spirilla.
- .44 Higher Bacteria. Also Yeasts and Moulds.
- .45 Cryptogenic Infections (Organism still undetermined).
- .46 Protozoa.
- .47 Flat Worms.
- .48 Round Worms.
- .49 Insecta and Arachnida.

.5 DISORDERS OF METABOLISM AND INTOXICATIONS.

- .51 Diseases Associated with Changes in the Blood and Blood-forming Organs.
 - .511 Chlorosis.
 - .512 Splenomegaly with Polycythæmia.
 - .513 Splenic Anæmia. Banti's Disease.
 - .514 Leukæmia.
 - .515 Hodgkin's Disease.
 - .516 Pernicious Anæmia.
- .52 Intoxications Associated with Disorders of Ductless Glands.
 - .521 Exophthalmic Goitre.
 - .522 Myxœdema.
 - .523 Cretinism.
 - .524 Acromegaly.
 - .525 Achondroplasia.
 - .526 Status lymphaticus.
- .53 Diseases due to Autochthonous or Heterochthonous Poisons of Organic Nature.
 - .531 Acute Yellow Atrophy.

- .54 Diseases due to Heterochthonous Poisons of Inorganic or Plant Nature.
 - .55 Arterio-sclerosis.
 - .56 Diseases due to Defects of Nutrition.
 - .57 Diseases of Disordered Metabolism.
 - .58 Organic Nervous Disorders.
 - .59 Functional Nervous Disorders.
- .6 RETROGRESSIVE CHANGES.
- .61 Atrophy.
 - .62 Degenerations.
 - .621 Acute, toxic, cloudy swelling.
 - .622 Fatty, Atheromatous.
 - .623 Mucoid.
 - .624 Hyaline and Fibro-hyaline.
 - .625 Amyloid.
 - .626 Colloid.
 - .627 Calcareous.
 - .628 Hydropic and Cystic.
 - .629 Keratinization. Degenerations with Overgrowth of Fibrous Tissue. Arterio-sclerosis.
 - .620 Various. Osseous, Gelatinous, Elastoid, Waxy, Fragmentation, Basophilic.
 - .63 Infiltrations.
 - .631
 - .632 Fatty.
 - .633 Biliary.
 - .634 Iron, Hæmosiderosis.
 - .635 Metallic.
 - .636 Other pigments.
 - .637 Anthracosis.
 - .64 Concretion. Calculus Formation.
 - .65 The Necroses.
 - .66 Stenosis due to Disease.
 - .67 Dilatation due to Disease.
- .7 PROGRESSIVE CHANGES.
- .71 Regeneration.
 - .711 Hypertrophy.
 - .712 Metaplasia.
 - .72 Hypertrophy.
 - .73 } Benign Tumours (of one of the modifications of fully
 - .74 } formed connective tissue).

- .75 Benign Tumours (of Epithelial Origin).
- .76 Indeterminate Group (Tumours of Uncertain Histology or Malignancy).
- .77 Malignant Tumours. Sarcoma, Tissue-forming Varieties.
- .78 Malignant Tumours. Sarcoma.
 - .781 Round-celled Sarcoma.
 - .782 Spindle-celled Sarcoma.
 - .783 Mixed-celled Sarcoma.
 - .784 Giant-celled Sarcoma.
 - .785 Melanotic Sarcoma.
 - .786 Lymphosarcoma.
- .79 Malignant Tumours of Epithelial Origin.
 - .791 Epithelioma.
 - .792 Carcinoma Simplex (Spheroidal-celled).
 - .793 Carcinoma Simplex, Medullary type.
 - .794 Carcinoma Simplex, Scirrhus type.
 - .795 Columnar-celled Carcinoma.
 - .796 Adenocarcinoma.
- .70 Cystoma.
- .8 TRAUMATA (from Mechanical, Chemical, or Physical Causes).
 - .81 Wounds.
 - .811 Incised.
 - .812 Punctured.
 - .813 Contusions.
 - .814 Lacerations.
 - .815 Crushing Accidents.
 - .816 Gunshot Wounds.
 - .817 Bedsores.
 - .818 Abrasions.
 - .819 Ruptures.
 - .82 Fractures.
 - .83 Dislocations and Sprains.
 - .84 Displacements.
 - .841 Hernia.
 - .842 Intussusception.
 - .843 Volvulus.
 - .844 Prolapse.
 - .85 Impaction of Foreign Bodies.
 - .86 Thermal Injuries.
 - .87 Chemical Lesions.
 - .88 Pressure Effects produced by compression or traction from without, or distensions from within.
 - .89 Birth Processes.

.9 OPERATIVE PROCEDURES.

- .91 Amputations.
- .92 Excision.
- .93 Plastic.
- .94 Ligature.
- .95 Incision.
- .96 Union and Replacement.
- .97 Fixation.
- .98 Experimental Surgery.
- .99 Miscellaneous Operations.

LIST OF ABBREVIATIONS USED IN THIS CATALOGUE

Ref.	= Reference.
E. or E. No.	= Museum Entry number.
P.M.	= Post Mortem or Autopsy.
A.	= " " "
S.	= Surgical.
R.V.H.	= Royal Victoria Hospital, Montreal.
M.G.H.	= Montreal General Hospital.
P.H.I.	= Protestant Hospital for Insane, Montreal.
St. Bart's.	= St. Bartholomew's Hospital, London.
A.M.M.	= Army Medical Museum, Washington, D.C.

CATALOGUE AND INTRODUCTIONS

BY

O. C. GRUNER

- 41. BONE-MARROW
- 42. LYMPH-NODES
- 43. SPLEEN
- 44. THYMUS GLAND

41. BONE-MARROW

INTRODUCTORY

THE varying condition of the bone-marrow is most conveniently observed in the sternum, where there is an abundance of formative tissue, and sufficiently scanty compact bone to prevent the task of opening the interior from being irksome. The series of specimens here exhibited expose to view the long axis of the bone, with the exception of 41.61², which shows the appearance on cross section. While the sternum forms so convenient a material for study, valuable specimens are also afforded by the tibia (41.711²), femur (41.515¹), vertebræ, &c. This is important in view of the fact that circumstances may arise under which the examination of the sternum is not permissible at autopsy. Where a permit for abdominal incision only is received, the lumbar vertebræ may be examined by sawing out a small wedge. Where no permit is received at all, it is feasible to employ a trocar for drawing enough marrow from the head of the tibia to enable a histological examination to be made. In this case the fact that the marrow tissue is much more abundant and much redder in the lumbar vertebræ must be taken into consideration before pronouncing on the character of the change.

The *naked-eye points to observe* in the series are : (1) the relative proportion between marrow tissue and compact bone, (2) the colour of the marrow, (3) the texture of the cut surface, (4) the abundance of bone trabeculæ, (5) the occurrence of fat.

The differences shown with successive ages will be noticed to depend on the formative activity of the marrow tissue rather than on the age itself ; thus 41¹ (from an infant) is no different from 41.711¹⁰ (aged 43) as far as the naked eye will show ; 41.711¹ (aged 16) is very similar to 41.711² (aged 58).

The *essential changes* exemplified by the series are those of (1) increased formative activity (41.711^{1,7}) ; (2) diminished formative activity (41.61¹) ; (3) actual degenerative change dependent on acute intoxication (41.620¹⁻²) and malnutrition (41.61³) ; (4) atrophic changes (41.61²).

The term 'increased formative activity' signifies an increased production of either red cells or white cells or both. If the main phenomenon is red-cell formation, the marrow is called erythroblastic, if

white-cell formation the term leucoblastic is applied. In either case there are three main features present : (a) redness up to a prune-juice colour ; (b) paucity of bone trabeculæ (41.711²) ; (c) abundance of marrow tissue (41.711³). The second and third points are interdependent. When the bone is cut open, the marrow tissue is found soft and tends to run or ooze out beyond the surface of the cut, while the scarcity of bone is evidenced by the ease with which a knife-tip or the finger-nail will indent the central parts of the bone. In 41.711⁵ and 41.711⁶ the abundance of the marrow tissue is the more striking because the compact layer is very much thinned out, and the sternum appears much thicker than usual owing to the large amount of red-coloured tissue between the opposite surfaces.

Increased formative activity is not always associated with redness, as shown in 41.711³, where the tissue is pale ; and 41.711² and 41.711¹⁰, where the cut surface is brightly mottled with red and yellow. Paucity of bone trabeculæ, however, is always characteristic, as well as the third point—that of abundance of marrow tissue.

It is not possible to decide by the naked eye between a leuco- and an erythro-blastic reaction ; 41.711¹¹ and 41.514¹, for instance, do not appear to be very different. The terms were obviously introduced with the study of this tissue under the highest powers of the microscope, and cannot be expected to coincide with naked-eye characters.

It has been found convenient in this Catalogue to designate all these marrows as 'hyperplastic', since, in a general way, all of them are of this nature.

Diminished formative activity may be dependent on definitely atrophic conditions, or may be the result of degenerative processes. Inhibition of formation may also arise under the influence of certain morbid agents. The distinctive features are different in the two cases. In atrophies, the bony trabeculæ are scanty, so that the cut surface of the bone is very decidedly honeycombed. But more than that, hardly any marrow substance is found to be present, inasmuch as the honeycomb-like spaces appear empty. In other cases, the atrophy of the marrow is associated with a preponderance of bony trabeculæ, the cut surface being highly resistant to knife-tip or finger-nail, and the pits in which the marrow lies are found to be very minute. This condition amounts to one of sclerosis of bone, and is due to inflammatory causes, or may be part of a general senile tendency to ossification of connective tissue. It is easy to see how premature sclerosis may destroy the available space for marrow tissue, and so interfere with recovery

from such infections as demand vigorous over-growth of the formative cells.

Degenerative changes are shown by the great pallor and semi-translucence of the tissue. In some cases (41.620¹) the translucence is marked and justifies the diagnosis of *gelatinous degeneration*—a condition still more conspicuously discernible in microscopic sections because the formative cells are very few, and expose an abundant hyaline and pale pink staining material. This is well shown in the microphotograph of 41.620¹.

Another form of reaction met with in the marrow is that known as *lymphadenoid*. This term is used to indicate the production of an undue number of non-granular cells of the white-cell series. The naked-eye appearance of such a marrow is that of a pale, rather abundant, tissue, well filling moderately large marrow-spaces. The condition is exemplified by 41.515¹, although it will there be seen that there is little indication of specific marrow changes as far as the naked eye will show. A lymphadenoid reaction is not uncommon in a variety of conditions besides the one named.

The student will gather from the above remarks that he will not be able to diagnose morbid conditions of the bone-marrow in anything but a very general way, and he is introduced to the subject more for the purpose of showing him that the bone-marrow does vary a little macroscopically, than for the purpose of suggesting there is any possibility of identifying any given disease from their inspection. In this respect we encounter a wide difference from other organs of the body.

It is essential to realize here that the highest powers of the microscope alone enable one to form an opinion of the nature of the marrow tissue, film preparations being made and differential counts instituted for the purpose, as in the investigation of the blood itself.

The conclusion is also forced upon the student that no marrow state is pathognomonic of any disease, but that any of the types exhibited in this series may be found in any morbid state. A simple microbic infection in a distant part of the body will be associated with an erythroblastic, or leucoblastic, or degenerative, or atrophic marrow, according to various factors, the chief of which perhaps is the personal peculiarity of the patient's 'resisting power'.

When the infective process occurs in the bone itself, we have before us examples of various forms of osteomyelitis, which are best studied in connexion with this subject (Section 9).

O. C. G.

DETAILED CONTENTS OF SECTION

41. BONE-MARROW

Abundant	41.711 ^{1,2,3,5,6,7} .
Age	41 ¹ Infant ; 41 ² Child ; 41.61 ⁴ (old).
Anæmia, Bone-marrow in,	
Secondary	41.61 ¹⁻⁴ .
Pernicious	41.516 ¹ .
Arterio-sclerosis, Marrow in	41.61 ² ; 41.711 ¹⁰ .
Atrophy of	41.61 ¹⁻⁴ .
Cancer, Marrow in	41.61 ³ ; 41.620 ² .
Child, Bone-marrow in	41 ² .
Colour, Red	41.711 ¹⁰ (focal) ; <i>see also</i> Red bone-marrow.
Congenital syphilis	41 ¹ .
Congestion, Focal	41.61 ³ ; 41.711 ¹⁰ .
Degenerative marrow	41.61 ⁴ ; 41.620 ^{1,2} .
Endocarditis, Marrow in	41 ² ; 41.711 ^{1,5} .
Erythroblastic marrow	41.711 ¹ .
Febrile marrow	41.711 ^{2,3} .
Femur	41.515 ¹ .
Focal congestion ; <i>see</i> Congestion.	
Fragilitas Ossium, Bone-marrow in	41.514 ¹ .
Gelatinous	41.620 ^{1,2} .
Histological characters	
Erythropoiesis diminished	41.514 ¹
Drawings	41.711 ⁴ ; 41 ¹ ; 41.711 ¹ .
Photographs	41.620 ¹ .
Hodgkin's disease, Bone-marrow in	41.515 ¹ .
Hyperplastic	41.711 ^{1,2} ; 41.711 ^{10,11} (focal). Quoted in 43.514 ^{3,13} .
Inanition, Bone-marrow in	41 ¹ .
Infant, Marrow of	41 ¹ .
Leucoblastic marrow	41.711 ^{4,5,6} .
Leukæmia, Bone-marrow in	41.514 ¹ .
Lymphosarcoma	41.786 ¹ .
Malnutrition, Bone-marrow in	41.61 ³ .
Osteomyelitis, Bone-marrow in	41.711 ² .
Pernicious anæmia ; <i>see</i> Anæmia.	
Puerperal fever, Bone-marrow in	41.711 ⁴ .
Purpura, Bone-marrow in	41 711 ⁷

Red marrow	41.61 ³ ; 41.711 ^{1,2,7} . Quoted in 43.575 ¹ .
Renal disease, Bone-marrow in	41.61 ^{1,2} .
Sarcoleukæmia, Bone-marrow in	41.514 ¹ .
Secondary anæmia; <i>see</i> Anæmia.	
Semi-translucent marrow	41.515 ¹ ; 41.620 ^{1,2} .
Septicæmia, Bone-marrow in	41.711 ¹¹ .
Sublymphæmic	41.514 ¹ .
Syphilis, Bone-marrow in	41.711 ¹⁰ ; 41 ¹ .
Toxæmia, Bone-marrow in	41.620 ¹ .
Tuberculosis, Bone-marrow in	41.711 ⁶ .
Typhoid, Bone-marrow in	41.711 ³ .
Uræmia, Bone-marrow in	41.61 ^{1,2} .

41. BONE-MARROW

CATALOGUE*

Anatomical Series

(The two specimens directly below, Nos. 41¹ and 41², showing the appearance of the normal bone-marrow, are introductory to the pathological series following.)

41¹ Bone-marrow of an Infant.

The specimen shows the relative amount of bony and marrow tissue at this age. The marrow is extremely dense, dark red in colour from vascularity, especially near the epiphysis, against the white of which it stands out in marked contrast. Trabecular tissue is inconspicuous.

An original coloured drawing is also shown from a microscopic section taken from this specimen at a point where there are few bony trabeculæ, so as to afford a field without any bone visible. Two large cells are seen, one with a pale vesicular nucleus, the other with multiple fragmenting nucleus. A number of small cells, obviously lymphocytes, are scattered about. Some cells, three or four times as large, occur at the right border. These are myelocytes. A large degenerating cell is also shown, besides a number of erythrocytes. Three eosinophiles are present. This shows the average cellular composition of normal bone-marrow. (Hæm. and Eosin, Zeiss Imm. Oc. 6.) The detailed cell-characters can only be ascertained by special stains.

M. L., aged 4 months. Died of inanition. He had been fed on Nestlé's milk since birth, which was premature (8th month). Signs of congenital syphilis were present.

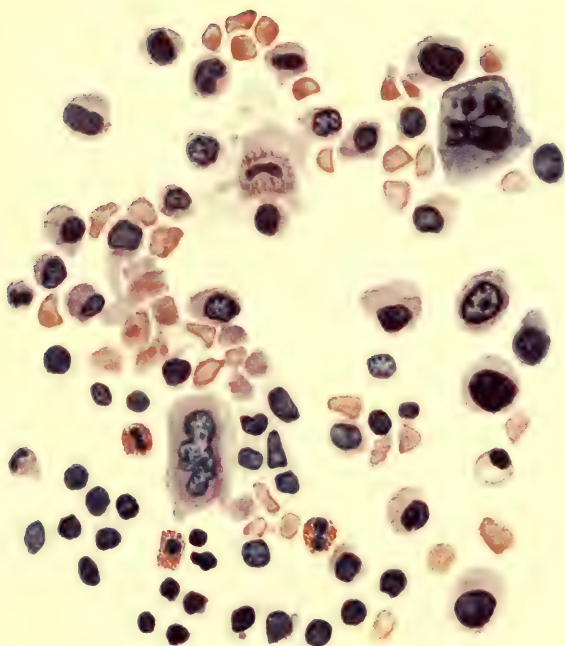
P.M. Showed apparently normal organs.

Ref. : E. 5244. R.V.H. 111.12.

PRESENTED by Dr. Gruner.

* For abbreviations used in this Catalogue see page xviii.

PLATE I



41' BONE-MARROW OF AN INFANT FROM TRANSVERSE
SECTION OF NORMAL STERNUM

Hæm. & Eryth. Zeiss imm. oc. 6

Presented by Dr. Gruner

41² Bone-marrow in a Child.

The specimen shows a small sternum sawn longitudinally. The marrow tissue is divided off by three cartilage septa, two of which are very broad. The shell of compact bone is rather thick. The marrow tissue is very red and the supporting bone trabeculae very firm but not visible.

R. R., female, aged 9, admitted March 13th, died April 9th. A case of endocarditis following recurrent attacks of acute rheumatic fever. Died from failure of compensation.

P.M. Pericarditis, adherent pericardium, recurrent granular endocarditis, mitral stenosis, aplasic aorta, multiple infarcts of lungs, lobar pneumonia, fibrinous pleurisy, advanced fatty nutmeg liver, purpura, anasarca.

Ref.: E. 5501. R.V.H. 40.13.

PRESENTED by Dr. Gruner.

*Pathological Series.***.1 ANOMALIES.**

None in this series.

.2 CIRCULATORY DISTURBANCES.

See Cat. No. 41.61³.

.3 INFLAMMATIONS.

See under .4 Infections.

.4 INFECTIONS.

See under 41.620 Gelatinous Degeneration and 41.711
Hyperplasia.

.5 GENERAL OR CONSTITUTIONAL DISEASES.

.51 Diseases of the Blood and Blood-forming Organs.

.514 Leukæmia.

41.514¹ Bone-marrow in an Atypical Leukæmia.
(Sarcoleukæmia.)

The marrow tissue is very mottled in colour, parts being intensely injected. It is very abundant, and the trabeculæ are scanty, allowing the medulla to be easily cut with a knife.

Mrs. L. M., aged 72, was admitted to the R.V.H. Dec. 2, 1911, with pains in the bones, enlarged glands, and pain in the abdomen. Death occurred the following day after 24 hours' stupor. The spleen was enlarged. The blood-count gave: Reds, 2,360,000; Whites, 10,000; Hb, 50%. The cerebro-spinal fluid contained 4.8 grm. urea per litre.

P.M. Sarcomatosis. Tumours in left rib, liver, kidneys, pancreas, meninges, and thyroid. Spontaneous fracture of affected rib. Osteosclerosis of bones of skull. Subcutaneous hæmorrhage into psoas, under mucosa of bladder into uterus, and into floor of fourth ventricle. Atheroma of aorta. All the ribs were very fragile. The vertebral column could be cut with a knife. *Fragilitas Ossium*.

Micro. Exam. Marked changes in the direction of preponderance of lymphoidocyte cells, marked diminution of myelocyte forms, and diminution of erythropoiesis.

Note. A sublymphæmic change in the blood with the appearance of Rieder cells and myelolymphocytes. A small spleen whose cytology resembles that of a leukæmic spleen. Histological changes in the glands approximating those seen in lymphatic leukæmia, though not conspicuously enlarged.

Reported in full, in R.V.H. Bulletin No. 2, August 1912, under title 'Subleukæmic Sarcoleukæmia'.

Ref.: E. 4784c. R.V.H. 169.11.

PRESENTED by Dr. Gruner.

.515 Hodgkin's Disease.**41.515¹ Marrow of Femur in Hodgkin's Disease.**

A portion of the upper end of the femur opened to show the pale pink, soft, semi-translucent marrow permeating the trabecular masses. The tissue shows diffuse caseation of moderate grade.

Male, aged 27. Ill for nine months with fever and swollen lymph glands.

P.M. Combined tuberculosis and Hodgkin's disease. Change in liver, spleen, pancreas, femur, and retroperitoneal lymph glands.

See also specimens No. 42.515² and 43.515², and under Liver and Pancreas.

Ref. : E. 5097d.

PRESENTED by Prof. de Josselin de Jong, Rotterdam.

.516 Pernicious Anæmia.**41.516¹ Bone-Marrow in Pernicious Anæmia.**

This specimen shows the sternum rich in marrow of rather pale colour, but uniform in tint. The bone trabeculæ are just distinguishable.

This marrow presents the natural or average naked-eye appearance of an adult marrow, although it comes from a case in which marked changes would be expected (pernicious anæmia).

A. T., female, aged 34. Admitted to the R.V.H. Nov. 27, 1912, with signs and symptoms of severe anæmia of six months' duration.

Nov. 30th, Reds, 1,270,000 ; Whites, 1,800 ; Hb, 20%

Dec. 8th, ,, 780,000 ; ,, 2,700 ; ,, 10%

Dec. 16th, ,, 970,000 ; ,, 3,400 ; ,, 10%

Died with multiple hæmorrhages.

P.M. Cryptogenetic anæmia, fatty degeneration of organs. Hæmosiderosis of liver. The spleen was moderately enlarged. Its outer surface showed moderately conspicuous Malpighian follicles and a relative increase in the amount of fibrous tissue. The pulp was rather soft. Notching was natural. The sternum was cut in half to show the pale marrow ; where fresh it was moderately deep purple in colour, but not typically of pernicious type. Bone-marrow was abundant, rather firm, and almost glistening in some places. The bone trabeculæ were abundant.

(See also Specimens Nos. 43.516, 37.63.)

Ref. : E. 5375. R.V.H. 174.12. *Canadian Practitioner and Review*, March 1912.

PRESENTED by Dr. Gruner.

.6 RETROGRESSIVE CHANGES.**.61 Atrophy.****41.61¹ Atrophic Bone-marrow in Anæmia.**

The marrow is very scanty, of a pale colour throughout. The bone is thinned also, so that the total volume of the marrow is very small. The excess of bone is shown by the honeycombed appearance.

This change is the result of atrophy of the marrow tissue proper, while the bony trabeculæ have shared in the general atrophy.

J. W., male, aged 25. Admitted to the R.V.H. on August 30, 1911, with signs of uræmia (dyspnœa, continuous epistaxis). He had been ill six weeks. Red cells 750,000, whites 10,000.

P.M. Chronic mixed nephritis. Chronic adhesive pleurisy. Hypertrophy and dilatation of the heart. Fatty liver. Hyperplastic spleen and lymph-nodes. Ecchymoses of stomach.

Ref. : E. 4729. R.V.H. 145.11.

PRESENTED by Dr. Gruner.

41.61² Atrophic Bone-marrow.

This specimen shows almost exactly the same change as the preceding specimen. The marrow is here shown in cross section in place of longitudinal.

T., male, aged 53. Admitted to the R.V.H. April 17, 1912, in a state of uræmia from which he died on the day of admission. He had had convulsions for four days.

P.M. Chronic interstitial nephritis. Arterio-sclerosis of main arteries. Atrophic spleen. Atrophic marrow.

Ref. : E. 4971a. R.V.H. 54.12.

PRESENTED by Dr. Gruner.

41.61³ Atrophic Bone-marrow from Malnutrition.

The specimen shows focal congestion, but is chiefly of grey-yellow colour. The marrow tissue is abundant, completely filling up the sternum from compacta of one surface to that of the other. The compact tissue is thin.

Bone trabeculae through the marrow tissue are inconspicuous.

S. C., female, aged 63. Admitted to the R.V.H. on Jan. 22, 1913, for stomach trouble of many years' duration, but worse during the last 6 months. Whites count 18,000.

P.M. Carcinoma of cervix, extending to all adjoining organs. Bilateral hydronephrosis. Atrophy of spleen, marrow, and all organs.

Ref. : E. 5398. R.V.H. 9.13.

PRESENTED by Dr. Gruner.

41.61⁴ Atrophic Bone-marrow in Secondary Anæmia.

The sternum opened to show a very fragile spongy centre with a very soft, scanty, pale bone-marrow. The appearance is the result of degenerative changes and breaking down of the marrow tissue.

M. McK., female, aged 60, was admitted to the R.V.H. Nov. 21, 1912, suffering from gastric symptoms. The condition was of more than seven years' duration and consisted of recurrent attacks of severe dyspepsia, latterly hæmatemesis. Red cells, 2,600,000; white cells, 6,000; Hb, 65%. Operation revealed hour-glass stomach with adhesions. Death 13 days later. The case gave an interesting X-ray picture during life.

P.M. Hour-glass stomach. Enterogastrostomy. Plastic peritonitis. Death from asthenia. Old gastric ulcer. Senile atrophy of organs. Enlarged mesenteric and lumbar glands. Accessory spleen.

Ref. : E. 5401c. R.V.H. 164,12.

PRESENTED by Dr. Gruner.

.62 Degenerations.**.620 Gelatinous Degeneration.****41.620¹ Gelatinous Bone-marrow in Toxæmia.**

The marrow tissue is extremely abundant along the whole of the manubrium. It is maroon-coloured, and the central parts are quite semi-translucent, the distribution of this degenerative change being quite irregular. Bony trabeculæ are inconspicuous.

T. T., male, aged 55. Admitted to the R.V.H. on Feb. 12, 1913, for extravasation of urine, dying two days later. He had had difficulty of micturition 10 years. Admitted toxæmic, with local parts gangrenous from diffusion.

P.M. Septic cystitis and pyelitis. Passive congestion of organs. Fibroid myocardium (extreme). Edema of lungs.

Micro-photograph. Shows a number of small fat spaces of fairly uniform size; between these are a few small round cells with deeply staining nuclei, the marrow cells. One-third of the photo shows much dense grouping of the cells, and some larger forms (or megalokaryocytes) are present among them. The feebly stained structureless matrix between the fat spaces is degenerate material that gives the character to the condition.

Ref. : E. 5338. R.V.H. 14.13.

PRESENTED by Dr. Gruner.

41.620² Gelatinous Bone-marrow.

A sternum sawn longitudinally, showing a rather abundant marrow tissue in which bone trabeculæ can be readily seen. The compact layer is thick. The marrow tissue itself is mottled red and yellow; the yellow areas are rather translucent.

E. P., male, aged 46. Admitted April 21st, died April 22nd. Has suffered from pain in epigastrium, vomiting, and loss of weight for one year, admitted in a moribund condition.

P.M. Primary carcinoma of the pylorus (secondary in liver) leucoplakia of œsophagus, dilated aorta, fatty aorta and coronaries, emphysema, gastrectasis.

Ref. : E. 5520. R.V.H. 46.13.

PRESENTED by Dr. Gruner.

.7 PROGRESSIVE CHANGES.**.71 Regeneration.****.711 Hyperplasia.****41.711¹ Bone-marrow of a Young Adult. (Hyperplasia in Malignant Endocarditis.)**

This shows oblongs of deep red marrow, homogeneous in character and neither soft nor hard. The bony trabeculæ are conspicuous throughout the tissue.

An *original coloured drawing* is also shown from a microscopic section of this specimen *showing the erythroblastic and leucoblastic reaction*. Red cells of various shapes are seen (distorted by the process of smearing). At the right hand is a normoblast above and two megalocytes with fragmented nuclei below. The other cells of greenish tint and bearing fine granules are various forms of myelocytes. At the upper edge is a mast cell with feebly coloured granules and an eosinophile with dark purplish granules. (Triacid Stain. Zeiss Imm. Oc. 12.)

W. S., male, aged 16. Admitted to the R.V.H. on Dec. 4, 1912, because of endocarditis following attacks of rheumatic fever seven weeks and two years previously. He had had mastoid disease on the left side. He died on Dec. 17th. Reds, 4,420,000; whites, 10,600; Hb 51%.

P.M. Recurrent endocarditis (mitral and aortic). Hydrothorax (L.). Ascites, fatty liver, passive congestion of organs. Chronic tuberculous nephritis.

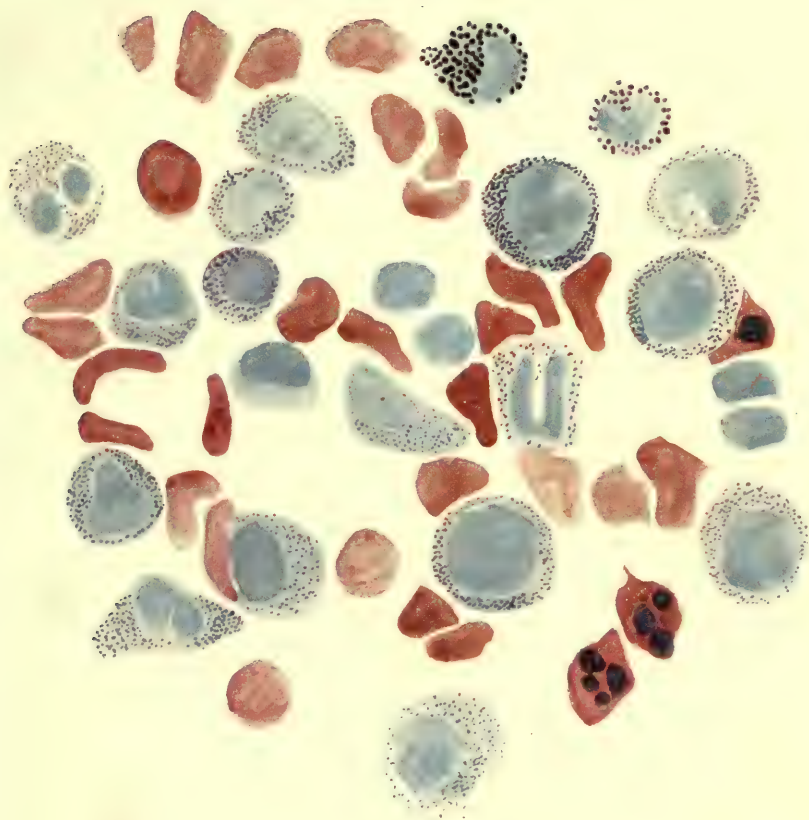
Ref.: E. 4785. R.V.H. 173.12.

PRESENTED by Dr. Gruner.

41.711² Bone-marrow of Febrile Type. (Hyperplasia in Acute Osteomyelitis.)

A portion of the tibia in section. The lower end of the specimen is very yellow in colour, but mottled with brilliant red markings. The upper end is of a uniform intense red. Marrow tissue is abundant, but is limited by a broad zone of compact bone on either side. Bony trabeculæ hardly occur through the medulla.

PLATE II



41.711' BONE-MARROW OF A YOUNG ADULT SHOWING
ERYTHROBLASTIC AND LEUCOBLASTIC REACTION

From case of Malignant Endocarditis

Triacid Stain. Zeiss imm. oc. 12

Presented by Dr. Gruner


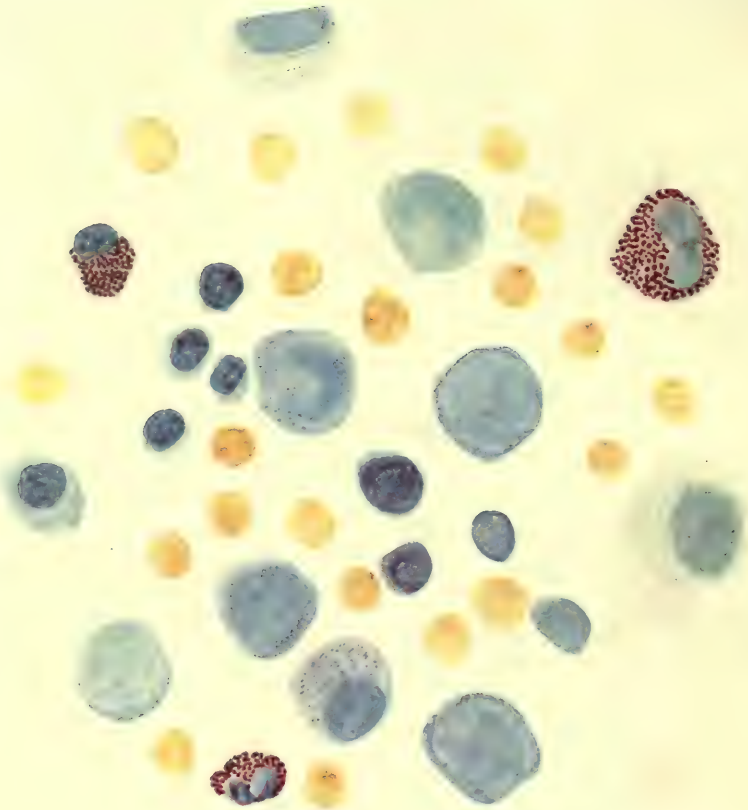


PLATE III



41.711⁴ BONE-MARROW SHOWING LEUCOBLASTIC REACTION

From a case of Puerperal Fever

Jenner Stain. Zeiss imm. oc. 12

Presented by Dr. Gruner

This specimen presents the typical prune-juice marrow characteristic of good reaction towards infections.

J. F., male, Italian, aged 58. Operated on in the R.V.H. on Dec. 6, 1912, for osteomyelitis. The leg was amputated below the knee.

Microscopic examination shows loose cedematous marrow tissue.
Ref. : E. 5350. R.V.H. S. 2626.12.

PRESENTED by Dr. Gruner.

41.711³ Diffluent Bone - marrow in Febrile State. (Hyperplasia.)

The specimen shows an exuberance of brownish marrow, oozing out from between the trabeculæ, which are everywhere present. The colour is rather pale, but uniform. The compact bone at the edge is scanty.

Mrs. H. C., aged 35. Admitted to the R.V.H. April 13, 1912, with obscure abdominal symptoms. She had been ill for three months. There was evidence of peritonitis. She died next day.

P.M. Typhoid fever with perforation of ulcer and general suppurative peritonitis. Mesenteric and lumbar adenitis.

Ref. : E. 4963. R.V.H. 51.12.

PRESENTED by Dr. Gruner.

41.711⁴ Painting of Microscopic Section of Bone- marrow showing Leucoblastic Reaction.

This drawing shows the aspect of the normal marrow cells when stained by Jenner's method (consists of methylene blue). The red cells are of uniform size (stained yellow). Eosinophile leucocytes occur. Of the remaining large cells most are finely granular (purple)—the myelocytes of different forms—while two others have a deeply stained cytoplasmic ring—myeloblasts. Much more deeply stained smaller lymphoid cells are later generations, conveniently classed as 'indifferent' cells, because this stain does not allow of their better definition.

From a case of puerperal fever. (Jenner stain. Zeiss Imm. Oc. 12.)

PRESENTED by Dr. Gruner.

41.711⁵ Leucoblastic Bone-marrow.

A sternum sawn longitudinally to show a very abundant maroon-coloured marrow. The compact layer is very thin. The marrow tissue is supported by a considerable amount of bone, but this fact is only obvious by palpation. The marrow tissue is not quite as dark red as in 41.711⁴.

T. F., male, aged 40. Admitted March 28, died April 19. Typical history of endocarditis with failing compensation. Anasarca, dyspnoea, palpitation, cough and blood-stained sputum, Corrigan's pulse.

P.M. Recurrent malignant endocarditis (aortic), lobar pneumonia, pericardial effusion, degeneration of heart muscle, aneurysm below aortic valve, nutmeg liver, mixed nephritis, old infarcts of spleen and kidneys, dilated arch of aorta, dilatation of heart.

Ref. : E. 4570. R.V.H. 37.13.

PRESENTED by Dr. Gruner.

41.711⁶ Leucoblastic Bone-marrow.

Sternum sawn in half to show a very abundant dark-red marrow. The compact layer is reduced to a mere shell, the sternum being wholly occupied by a soft trabecular tissue obscured from view by the marrow tissue proper. Two cartilage septa appear across the red areas. This is an instance of a leucoblastic tissue.

A. C., aged 32. Admitted June 27th, died Oct. 9th.

P.M. Tuberculosis of left hip with chronic suppuration, tuberculous broncho-pneumonia with cavities in right apex, calcified tubercles of spleen and bronchial glands, atrophic pancreas, miliary tuberculosis of diaphragm, sinuses in thigh.

Ref. : E. 5330. R.V.H. 140.12.

PRESENTED by Dr. Gruner.

41.711⁷ Bone-marrow in Purpura.

The specimen shows a bright-red abundant marrow of firm consistence. The bony tissue is obscured by a preponderance of marrow tissue.

A. E., male, aged 11, was admitted to the R.V.H. Feb. 19, 1913, suffering from purpura hæmorrhagica, supposed to be hæmophilic.

P.M. Purpura, petechial hæmorrhages throughout the body, anæmia of organs, hæmolymph nodes, hæmorrhagic appendicitis, persistent thymus, small spleen. There were necroses in the lymphoid follicles.

Ref. : E. 5415. R.V.H. 15.13.

PRESENTED by Dr. Gruner.

41.711¹⁰ Bone-marrow showing Focal Hyperplasia.

The marrow tissue itself is excessively abundant, and is much mottled with alternating areas of congestion and pallor. The bony trabeculæ through it are abundant.

The congested foci are areas of intense hæmopoiesis.

M. S., male, aged 43. Admitted to the R.V.H. for headache and loss of power on left side, symptoms of which existed three weeks. Death two days later from heart failure.

P.M. General luetic arterio-sclerosis, cor bovinum, nutmeg liver, mottled kidney.

Ref. 4728. R.V.H. 142.11.

PRESENTED by Dr. Gruner.

41.711¹¹ Bone-marrow in Septicæmia. (Focal Hyperplasia.)

Longitudinal section of sternum to show the marrow. The marrow is dark coloured, mottled with pale areas of punctate form ; towards the lower portion many of these areas are confluent. The compact bone is thin and dry. The trabecular structure of the central portion is easily seen.

A. V., male, aged 55, was admitted to the R.V.H. in August 1910, and an enlarged prostate was removed. Perineal abscess followed and septicæmia supervened. There were miliary abscesses in the kidneys and lungs, with septic pelvic phlebitis.

Ref. : R.V.H. 117.10.

PRESENTED by Dr. Gruner.

.78 Malignant Tumours. (Sarcoma.)**.786 Lymphosarcoma.****.41.786¹ Bone-marrow in Lymphosarcoma.**

A portion of sternum showing a very honeycombed bony network whose spaces contain translucent marrow. Portions of vertebræ are also present in which the marrow tissue is rather pale although the bony tissue is very dense.

Another portion of bone shows dark-red central marrow and similar change superficially to that seen in the vertebræ.

This specimen is more of historical interest than useful for the student. It merely exemplifies the condition of the marrow in the same case from which No. 44.786¹ is derived. (For history see this specimen.)

Ref. : E. 4900. R.V.H. 162.11.

PRESENTED by Dr. Gruner.

42. LYMPH-NODES

INTRODUCTORY

THE most conspicuous changes to be looked for in studying the naked-eye appearances of lymph-nodes are: (1) change of size, (2) change of colour, (3) replacement by new growth.

(1) *Change of size.* The ordinary variations are well exhibited in 42.361⁵, where all gradations from the normal to great bulk are shown in a series taken from one patient. The inflammatory changes incident to lymph-glands do not usually enlarge them more than the size shown in 42.351² or 42.361⁵, but when a number of enlarged nodes are massed together, as in 42.361⁷ and 42.516³, they give the impression of greatly increased bulk.

The character of the cut surface will afford some clue to the nature of the enlargement. It is here that change of colour calls for consideration.

(2) *Change of colour.* Ordinarily the lymph-node is very pale, almost quite white. Varying shades of redness are produced by congestion of different degrees up to that associated with intense inflammation. Very red nodes may be examples of adenitis or of hæmolymp nodes—two different conditions for whose differentiation the microscope must be invoked. The hæmolymp change may be regarded as a metaplasia (42.712¹) and consists in a metamorphosis of the lymphocyte-forming tissue into erythrocyte-destroying, and occasionally into erythrocyte-forming tissue. That is to say, the change amounts to one of formation of accessory spleens in unusual parts of the body. The impossibility of distinguishing between acute adenitis and hæmolymp nodes is the less remarkable because conversion into the latter may be produced by infective agents which sometimes act in one manner (inducing adenitis) and sometimes in another, leading to appearances only classifiable by the aid of the microscope. Thus, from the gross appearances, 42.351² may be equally typhoid adenitis or hæmolymp formation. Similarly 42.514² may be classified as specifically leukæmic, or as hæmolymp change.

The development of a lemon-yellow colour, especially in the form of irregular mottling, is usually due to tuberculous disease, though also met with in lymphosarcoma and Hodgkin's disease. In tuber-

culosis, in place of having a very finely granular sandy surface, the tissue shows a smooth, homogeneous, cheesy character. 42.361⁴ shows a mass of caseous cervical glands, in which the number, shape, outline, and consistence of the degenerative foci are sufficiently variable to demonstrate in the one specimen all the various changes that may be met with in tuberculosis in these structures. Accessories to diagnosis are supplied by noticing (1) the condition of the capsule, because tuberculous adenitis is so frequently associated with the formation of firm adhesions binding one gland to another; (2) the occurrence of calcareous change, as shown in 42.361². 42.627² is a specimen in which the whole gland was converted into a calculus; it lay at the bifurcation of the trachea.

As characteristic of tuberculosis in cattle 42.361²⁰ may be instanced, where the enormous size, mottling, radial streaking, fibro-caseous appearance, and calcareous change are specially noteworthy.

A change of colour that is very frequently observed is through various shades of grey up to intense black. This is the familiar *anthracosis* shown in 42.637¹. Sometimes such glands are fleshy and succulent, at other times they grate with the knife. 42.79¹ illustrates the association of anthracosis and infiltration with new growth—a phenomenon no more remarkable than is the association of carcinoma with tuberculosis in lymph-nodes.

Variations of shape do not occur in connexion with lymph-nodes, save those produced by fusion of adjoining glands.

Variations of consistence do not count for so much as obtains with other viscera. The glands are usually semi-elastic to the feel, and retain that character in the various morbid processes to which they are liable. In museum preparations the feature of consistence is of little value except in connexion with the process of calcification, which is unaltered by hardening fluids and is practically diagnostic of obsolete tuberculosis.

(3) *Replacement by new growth.* The commonest examples are metastatic associated with primary growth elsewhere: 42.79¹⁻⁸, a series also illustrating varying degrees of enlargement. 42.79⁶ is a very massive infiltration. The characters to look for in the cut surface of such glands are the same as those which would be found in the original tumours. Thus, 42.79⁷ is epithelioma, 42.79⁸ is acinous carcinoma, and 42.79⁴ is colloid carcinoma.

The sarcomas are divisible into two groups, those belonging to the true sarcoma class, and those which some authorities would consider as constituting transitions to lymphogranulomatosis (42.515⁴, 42.786¹, and 42.515⁵). These masses are often matted

together and show little when examined externally. The cut surface is, however, fairly characteristic, being fleshy, very finely granular, bulging, juicy, and either homogeneous or marked with small, irregular, very pale lemon-yellow foci of degeneration. Without the aid of a microscope it is not possible to draw any distinction between sarcoma and Hodgkin's disease even by noting the above points, and indeed there is room for much difference of opinion even when the microscope is employed.

It was stated that the existence of periglandular adhesions formed an accessory means of diagnosis of tuberculosis. Frequently enlargements of Hodgkin's disease are unencumbered by such adhesions (42.515³), though in a few cases the enlarged glands are bound together.

Cystic change in glands is exemplified by two specimens (42.70^{1,2}), and is apparently due to breaking down of new inflammatory tissue which has first enlarged the glands to a considerable degree.

There are certain considerations to be brought forward in order to give the student some idea of the processes at work in the lymph-nodes under the influence of morbid agents. It is evident that the naked eye gives very little real information, and a study of the microscopic preparations in this collection will reveal numerous points in which difficulty is likely to arise. Very briefly, the structure of the lymph-node is as follows: The cortical portion is made up of a collection of follicles of ovoid shape, each surrounded by a lymphatic sinus which receives material from without. The central portion is made up of pulpar tissue permeated by a close network of small channels draining the sinuses just named, and emptying into the efferent vessels. The two series of tissue have a separate series of vessels of supply, though these come off the main trunks which enter at the hilum. According as the brunt of change is borne by follicles, pulp, or sinuses, so the histological picture varies. Thus the simple inflammatory processes referred to involve the sinus system, and metastatic deposits become lodged here. There is, however, a whole series of morbid conditions, usually classed as blood diseases, which involve the other portions of the gland. In *Hodgkin's disease* and its variants, the changes are in the follicles and the immediate vicinity, as described at length in the Catalogue under specimen 42.786¹, where the morbid process has gone on to the lymphosarcomatous type. The pseudoleukæmias¹ are associated with changes in either follicular or pulpar tissue, which may

¹ What Cohnheim originally termed pseudoleukæmia is the aleukæmic stage of leukæmia, or lymphadenosis of Schridde and Aschoff. See Dr. Adami's note at end of this Introduction (page 31).—Ed.

be briefly described as processes of blurring of normal structure, the whole organ becoming lymphoid (small round-celled) in character. *Leukæmias* are associated with follicular and pulpar changes also, but the process is now one of metaplasia, or transformation of the tissue into one which produces either myelocytes or lymphoblastic cells, according to the type of leukæmia. The metaplasia is produced by a change of process of development of the specific cells lying in the pulp cells, which are essentially similar to those met with in the splenic pulp. Probably it is of minor importance whether the process is acute or chronic, but in the former class of case the clinical features of the disease affords evidence in favour of the view that acute leukæmia is due to an infective agent, whose nature must have several points in common with those possessed by better known infections. Histologically, too, there is the interesting fact that the eruptive fevers frequently show similar changes in the pulp of lymph-nodes to those found in leukæmia on a large scale, just as the blood in such cases is also liable to contain myelocytes.

The enlargement in *lymphatic leukæmia* (lymphadenosis with leukæmia) is well shown in 42.514¹. The reddish colour and succulent appearance of the cut surface and the moderate size are to be noted as points of distinction from an enlargement due to *lymphosarcomatous change*. In lymphosarcoma the tumour infiltrations are much paler and more closely connected with one another.

The dark colour of the glands in acute lymphatic leukæmia not infrequently gives them a close resemblance to hæmolymph glands and toxic adenitis. 42.514² affords a very good illustration of this point.

It is with a knowledge of the limitations to the information yielded by gross appearances that the student should approach the study of the specimens on the shelves. He will then not fail to examine the microscopic preparations, and piece together the complete pathological picture by adducing the clinical data with which the Catalogue provides him.

O. C. G.

[Inasmuch as the student is constantly being thrown into confusion by the different terminologies employed both by the text-books and his clinical teachers in connexion with the series of disturbances summarized above, it becomes necessary for us to state clearly what we understand by these various terms :

Hodgkin's disease (lymphogranulomatosis of modern authors, pseudoleukæmia of some earlier writers): a specific infective inflammatory hyperplasia of lymph-nodes.

Lymphadenosis: a diffuse, apparently non-inflammatory hyperplasia of lymphoid elements throughout the body which may or may not be accompanied by excess of lymphocytic elements in the blood:

(1) When so accompanied = Lymphatic leukæmia.

(2) When not so accompanied = Pseudoleukæmia of Cohnheim, aleukæmia or pre-leukæmic leukæmia of other authorities.

'Leukæmia' ought only to be spoken of as a symptom: we should speak of lymphadenosis with, or without, leukæmia.

Myelosis: a diffuse, apparently non-inflammatory, hyperplasia of the myelogenous elements of the bone-marrow and lymphoid tissues, which similarly may or may not be accompanied by leukæmia of the myeloid type.

(1) Myelosis with leukæmia = Myelogenous leukæmia.

(2) Myelosis without leukæmia = Aleukæmic leukæmia.

Lymphosarcoma and Lymphosarcomatosis. Any of the above conditions may show, either locally or generally, the development of malignancy, characterized by infiltrative growth of lymphoblastic or myeloblastic elements beyond the limits of the organ; such infiltrative invasion of other parts constitutes sarcoma; if diffuse, sarcomatosis.

J. G. ADAMI.]

(For a fuller exposition of this subject, see *The Principles of Pathology*, J. George Adami, vol. i, chap. xix.—Ed.)

DETAILED CONTENTS OF THE SECTION

42. LYMPH-NODES AND SYSTEM

Adenitis	42.31 ¹ ; 42.351 ¹⁻³ .
Age, Infant	42.361 ¹² .
Anatomical regions :	
Aortic	42.31 ¹ ; 42.515 ⁵ ; 42.79 ⁸ .
Axillary	42.79 ³ .
Cervical	42.361 ^{3,4,10} ; 42.515 ¹ .
Inguinal	42.79 ⁷ .
Mediastinal	42.361 ^{2,21} .
Mesenteric	42.351 ^{1-3,5,7,8,11,15} ; 42.514 ^{1,2} ; 42.64 ¹ ; 42.79 ⁵ . Quoted in 44.526 ^{1,2} .
Pelvic	42.79 ⁶ .
Peribronchial	42.361 ^{1,9,12} ; 42.515 ⁴ ; 42.627 ^{1,2} ; 42.712 ¹ ; 42.79 ^{1,2} ; 42.70 ¹ .
Periportal	42.72 ¹ .
Subcostal	42.515 ⁴ .
Tracheal; <i>see</i> Peribronchial.	
Animals, cow	42.361 ^{20,21} ; monkey, 42.361 ¹⁵ .
Anthracosis of	42.361 ² ; 42.627 ¹ ; 42.637 ¹ ; 42.712 ¹ ; 42.79 ¹ .
Appendicitis, Glands in	42.31 ¹ .
Bovine tuberculosis	42.361 ⁶ ; 42.361 ^{20,21} .
Calcified glands	42.361 ² ; 42.627 ^{1,2} ; 42.64 ¹ ; 42.79 ⁴ ; 42.70 ¹ .
Carbon-pigment in; <i>see</i> Anthracosis.	
Carcinoma of	42.79 ^{1,2,3,4,5,6,7,8} .
Scirrhous	42.79 ³ .
Colloid	42.79 ⁴ .
Squamous	42.79 ⁷ .
Softening	42.79 ⁷ .
Caseation of	42.361 ^{1,3,6-12,15,20,21} ; 42.72 ² .
Cirrhosis of liver, Glands in	42.72 ¹ .
Comparative anatomy; <i>see</i> Cow, Monkey.	
Congestion of	42.351 ^{1,2} ; 42.72 ¹ ; 42.79 ⁸ .
Cow	42.361 ^{20,21} .
Cystic	42.70 ¹ .
Fibrosis	42.515 ⁵ ; 42.637 ¹ .

Hæmolymp nodes	42.514 ² ; 42.515 ¹ ; 42.712 ¹ . Quoted in 42.514 ¹¹ .
Histological features of lymphatic glands :	
Dilated sinuses	42.31 ¹ .
Erythroblastic change	42.514 ² .
Fibrosis	42.515 ⁵ .
Hæmorrhagic areas	42.712 ¹ .
Loss of follicular structure	42.31 ¹ ; 42.351 ³ .
Necrotic foci	42.351 ^{2,3} ; 42.79 ⁸ .
Phagocytes in	42.712 ¹ .
Hodgkin's disease	42.515 ¹⁻⁵ ; 43.515 ²⁻⁵ ; 24.515; 37.515; 39.515; 57.515.
Hyperplasia of	42.72 ^{1,2} ; 44.526 ^{1,2} . Quoted in 41.61 ¹ .
Infant, Glands of	42.361 ¹² .
Lymphatic leukæmia	42.514 ^{1,2} .
Lymphosarcoma	42.786 ¹ .
Monkey, Gland of	42.361 ¹⁵ .
Necrotic change in glands	42.351 ² ; 42.79 ⁸ ; <i>see</i> Histological features.
Periadenitis	42.31 ¹ ; 42.515 ⁵ ; 42.361 ^{4,6,7,10,11,20,21} ; 42.72 ² ; 42.79 ⁶ .
Purpura	42.514 ² .
Softening of	42.361 ⁶ ; 42.79 ⁷ .
Solitary follicles, Large	44.526 ² .
Tonsils	44.526 ² .
Tuberculosis of	42.361 ^{1-12,15} . Tbc.* 39-44.
Bovine	42.361 ^{6,20,21} . Tbc.* 45.
Softening	42.361 ⁶ .
<i>See under</i> Caseation.	
Typhoid, Glands in	42.351 ¹⁻³ .

* Tbc. These numbers refer to specimens in Tuberculosis series of the General Pathology Section.

42. LYMPH-NODES

CATALOGUE *

.1 ANOMALIES.

None in this series.

.2 CIRCULATORY DISTURBANCES.

See under 42.711 Hyperplasia, also 42.515¹.

.3 INFLAMMATIONS.

.31 Catarrhal or Desquamative Inflammation.

42.31¹ Aortic Glands. Acute Toxic Adenitis. (Periadenitis.)

A portion of the abdominal aorta with adjoining lymph-glands. These are enlarged, and many are bound together by adhesions. Some are pale in colour and others fleshy.

L. M., male, aged 24. Admitted to the R.V.H. on July 10, 1912, with jaundice and abdominal pain of two days' duration, onset sudden. No blood-count. Operated on for cholecystitis. Widal negative on July 16. July 24, sutures gave way and liver appeared cystic. August 3rd, colon vaccine given. Died on August 13th.

P.M. Gangrenous appendicitis with pelvic abscess and suppurative pylephlebitis, general peritonitis, ascites, jaundice, general lymphadenitis, atrophy of gall-bladder, acute splenitis.

Micro. Exam. The lymphatic channels are widely dilated and in a state of catarrh. Follicular tissue is lost.

Ref. : R.V.H. 113.12. E. 5243d.

PRESENTED by Dr. Gruner.

* For abbreviations used in this Catalogue see page xviii.

.32 Exudative Inflammation.

None in this series.

.33 Destructive Inflammation.

See under **42.361 Caseous Tuberculosis.**

.34 Specific Inflammation due to Cocci.

None in this series.

.35 Specific Inflammation due to Bacilli.**.351 Lesions due to B. Typhosus.****42.351¹ Enlargement of Mesenteric Glands in Typhoid.**

The specimen consists of a piece of small intestine, cæcum, and appendix, with the glands in the mesentery at the angle. The posterior surface shows a gland cut open, the cut surface being granular and of pale colour. The anterior surface shows a typhoidal ulcer near the ileocæcal valve and a group of enlarged glands. One of these is very large and presents alternate dark and pale areas, the dark areas being probably originally red from congestion. The other glands of this group are much smaller than usual in a case of this kind.

Ref. : R.V.H. E. 561.

PRESENTED by Dr. Adami.

42.351² Mesenteric Glands from a Case of Typhoid Fever.

The specimen consists of a portion of the mesentery, the bowel having been removed. It is dissected to show that it is studded with elongated, bean-shaped, enlarged glands, many of which are cut across and present a deeply coloured dusky surface. The periphery is congested. The glands are all approximately of the same size.

C. A., male, aged 17, was admitted to the M.G.H., having been ill

with typhoid fever for 11 days. He died three days later from toxæmia.

P.M. Typhoid ulceration of ileum and cæcum, enlarged solitary follicles, infarct of spleen, acute splenitis, cloudy swelling of organs. Enlarged mesenteric glands with central necrosis.

Ref. : M.G.H. 207.09. E. 4064.

See also Specimen No. 43.325¹ and 43.351⁵.

PRESENTED by Dr. Wolbach.

42.351³ Mesenteric Glands, Typhoid Fever.

A chain of greatly enlarged glands lying in the mesentery. The largest mass is close to the appendix angle. The glands are pale and fleshy. Some are discrete, others are confluent.

H. B., male, aged 24, a trench labourer, was admitted to the R.V.H. on July 21, 1912, with symptoms of typhoid fever. He had been ill six days. The infection was apparently obtained on the Back River. 5,900 leucocytes per c.mm. Copious hæmorrhage on August 9th. Widal negative. Died August 10th, on 26th day of disease.

P.M. Enteric fever (three ulcers only) with death from hæmorrhage. Myasthenia cordis, cloudy swelling of organs, marked mesenteric and lumbar adenitis, acute splenitis.

Micro. Exam. There is marked catarrh of the lymph passages and the follicular arrangement has been largely lost. Characteristic necrosis is seen in the centres of the remaining follicles.

Ref. : E. 5242. R.V.H. 110.12.

PRESENTED by Dr. Gruner.

.36 Specific Inflammation due to Acid-fast Bacilli, &c.**.361 Lesions due to B. Tuberculosis.***Human Tuberculosis.***42.361¹ Tuberculosis of Peribronchial Glands.**

A group of enlarged glands about the bifurcation of the trachea, two the size of a walnut. The cut surface shows caseation, softening of the larger and anthracosis of the smaller glands.

Old Museum specimen.

42.361² Tuberculosis of Mediastinal Glands.

The specimen consists of a large, partly calcified, partly caseous, mass limited by a distinct capsule, situated in close relation to the aortic arch. Carbon-pigmented area can be seen through the capsule in some situations.

Ref. : E. 4002c.

See also specimen No. 43.72³.

PRESENTED by Dr. Klotz.

42.361³ Caseating Tuberculous Cervical Glands. (Removed by Operation.)

The specimen consists of 46 glands of varying size, arranged according to magnitude; the larger ones are laid open, and show a homogeneous cheesy surface. The largest presents an irregular puckering on its anterior surface. The glands possess a rounded smooth outline.

Ref. : E. 239. M.G.H. S. 100.96.

PRESENTED by Dr. Shepherd.

42.361⁴ Tuberculosis of Cervical Glands. (Removed by Operation.)

A nodular tumour the size of a kidney, consisting of enlarged glands which are adherent to each other, showing the appearances

of a mass of glands in a typical case of tuberculous adenitis of the neck.

Ref. : Old Museum specimen.

PRESENTED by Dr. Roddick.

42.361⁵ Tuberculosis of Mesenteric Glands.

Part of the mesentery, with the peritoneal covering dissected off to show enlarged glands, varying in size from a pea to an acorn.

K. McR., female, aged 32. Obsolescent tuberculosis of pleura and both lungs. Acute leptomenigitis from infection with *B. influenza*, causing death.

Ref. : R.V.H. 23.98. E. No. 38.

PRESENTED by Dr. Adami.

42.361⁶ Tuberculosis of Mesenteric Glands.

A mass of enormously enlarged glands, firmly adherent to each other. The appearances resemble bovine tuberculosis, but the specimen is from a human subject. Extensive caseation has occurred, and from some of the glands the contents have been lost, leaving what amount to abscess cavities.

PRESENTED by Dr. Adami.

42.361⁷ Tuberculosis of Mesenteric Glands.

A mass of mesenteric glands, varying in size from the normal to several centimetres in diameter. They are very closely packed and are bound together by adhesions, producing a lobulated mass. The cut surface of one is shown, to demonstrate the caseation which is present.

42.361⁸ Mesenteric Glands. Tuberculosis.

A piece of mesentery, showing a number of large oval glands. The largest measures $3 \times 1.5 \times 9$ cm.; many of them have a pink

colour; several of the glands have been laid open to show that they are almost completely caseated.

From a male Greek, aged 32. He was said to have been ill only three weeks; the symptoms were pulmonary.

P.M. Chronic ulcerative tuberculosis of lungs, with cavitation; miliary tuberculosis of kidney, liver, and peritoneum; tuberculous ulcers of intestine. The glands in the thorax were not involved. Tubercle bacilli were found in the peritoneum.

Ref.: E. 3855b. R.V.H. 106.09.

PRESENTED by Dr. Klotz.

42.361⁹ Caseous Tuberculosis of Bronchial Glands.

Two bronchial glands cut across to show caseous masses within. An indication of a septum shows that the specimen originally consisted of two discrete glands. The upper is entirely caseous, with the capsule intact except at the point of contact with the larger lower gland, where the caseation spreads continuously through, and almost entirely replacing it. The interior of the caseous area is lobed. The gland tissue itself is congested.

For history see 43.361¹¹. (Same case.)

Micro. Exam. The capsule is seen to be much thickened, and the structure of the gland is obscured by a mass of caseous tissue. Around it are some giant cells. The blood-vessels around these are intensely engorged. There is marked inflammatory cell infiltration along the trabeculæ. Endothelial hyperplasia was marked in some sections of other glands in the same case.

Ref.: E. 4364b. R.V.H. 115.10.

PRESENTED by Dr. Klotz.

42.361¹⁰ Caseous Tuberculosis of Glands of Neck.

The specimen consists of a lobulated gland cut open longitudinally. The outer surface is smooth with a few tags of adhesions; the cut surface shows irregular extensive caseation. The whole of one pole is involved, the other pole showing three or four discrete foci separated by gelatinous-looking fibrous tissue.

J. M., male, aged 21. Admitted to M.G.H. April 25, 1910, with indurated painless swelling in right side of neck, which was first noticed five months previously; it was then a small lump

the size of a marble and had increased gradually to the present size. A few days before admission almost choked with difficult breathing, and sought relief by operation on this account. The enlarged glands were enucleated entire on April 26th. No signs of tuberculosis in lungs and no bacilli in sputum.

Ref. : E. 4931. M.G.H. S. 10.252.

PRESENTED by Dr. Wolbach.

42.361¹¹ Tuberculosis of Mesenteric Glands.

A loop of bowel with the mesentery attached. In the mesentery is a mass of enlarged lymph-nodes, some of them discrete, others united together, forming a broad, rolled-up mass. Smaller pinhead-size nodules intervene between this and the bowel itself. The glands are very hard and the cut surface is pale ochre-coloured and almost homogeneous. In this respect the specimen simulates lymphosarcoma.

Micro. Exam. The tissue is occupied by large hyaline rounded bodies with caseous centres. There are large, well-formed giant cells in their periphery, and very sharply defined groups of mesolymphocytic elements here and there.

Ref. : E. 5603d. P.H.I.

PRESENTED by Dr. Kaufmann.

42.361¹² Tuberculosis of Bronchial Node in an Infant.

An infant's trachea with a large gland below the bifurcation. The cut surface reveals almost complete substitution by caseous matter, while there is linear marking by carbon infiltration.

F. M., female, aged 4. Admitted April 23rd. Died May 16th. Father died of tuberculosis at 32 years. Child semi-stuporose. Tubercle bacillus found in cerebrospinal fluid. There were a leucocytosis and scattered areas of moist râles throughout both lungs. Clinical diagnosis of miliary tuberculosis and tuberculous meningitis.

P.M. General miliary tuberculosis. Caseous tubercles of peribronchial and peritracheal nodes. Caseous tuberculosis of spleen. Miliary tuberculosis of pleuræ, peritoneum, lungs, spleen, liver, kidneys. Tuberculoma of pons. Tuberculous meningitis. Acute bronchitis. Tuberculous broncho-pneumonia. Acute cystitis. Internal hydrocephalus. Acute suppurative otitis media (bilateral). Acute suppurative mastoiditis (left).

PLATE IV



42.361¹⁵ TUBERCULOSIS OF MESENTERIC LYMPH-NODES IN MONKEY

Dr. Duval

Note. The bronchial glands appear to be the earliest site of tuberculosis. The amount of pus on the base of the brain was greater than usual.

Ref. : E. 3397. R.V.H. 55.07.

PRESENTED by Dr. Klotz.

Monkey Tuberculosis.

42.361¹⁵ Tuberculosis of Mesenteric Nodes in Monkey.

A specimen of small intestine with the mesentery attached. In the mesentery there are some enlarged glands, the largest of which measures 1 cm. in diameter, is slightly oval in shape, smooth, and hard, a few dilated capillaries run across it. The other glands are much smaller, but are hard in consistence; they are all discrete and show no trace of inflammation about them. One of the glands has been cut through to show its complete caseous transformation.

History. From a ring-tailed monkey that was in captivity about eight months, and died with symptoms of pulmonary tuberculosis and enteritis.

Micro. Exam. Section shows numerous giant and epithelioid cells and areas of necrosis.

Ref. : E. 2961. M.G.H.

PRESENTED by Dr. Duval.

*Bovine Tuberculosis.***42.361²⁰ Tuberculous Nodes from a Cow.**

A mass of greatly enlarged glands, partially dissected behind, the anterior surface formed by a longitudinal cut. This shows one large and three smaller masses of a dark yellow colour, traversed by delicate strands of fibrous tissue. The centre of the large mass presents a focus of bright yellow colour, indicative of caseous change. The surrounding tissues are thickened.

From a case of generalized bovine tuberculosis.

Ref. : E. 3204.

PRESENTED by Dr. Higgins, Government Bacteriological Laboratory, Ottawa.

42.361²¹ Bovine Tuberculosis of Mediastinal Glands.

A slab of tissue, the cut surface of which shows large rounded caseous masses bound together by firm fibrous tissue. Some white suet-like fat limits them off at the one end, and muscular tissue at the other. The individual masses are dotted with pale-yellow foci of calcification. These alternate with ochre-yellow cheesy areas and semi-translucent peripheral borders.

Ref. E. 3204.

PRESENTED by Dr. Higgins, Government Bacteriological Laboratory, Ottawa.

PLATE V



42.514' LYMPH-NODES IN LYMPHATIC LEUKÆMIA

Dr. Wolbach

.4 INFECTIONS AND PARASITES.

See 42.351¹⁻³, and 42.361¹⁻⁴.

.5 DISEASES OF METABOLISM AND INTOXICATIONS.**.51 Changes in Blood-forming Organs.****.514 Leukæmia.****42.514¹ Lymph-nodes in Lymphatic Leukæmia.**

A large mass of discrete, evidently enlarged, fawn-coloured lymph-glands, taken from the mesentery. One side has been dissected. The cut surface has a uniform, absolutely homogeneous appearance.

(For history see under Spleen, 43.514¹².)

Micro. Exam. shows the normal structure of the lymph-gland to be entirely lost. The tissue consists of uniformly distributed, closely packed, small, round, mononuclear cells, separated into large masses by scanty thin bands of fibrous tissue. With the oil-immersion lens these cells are seen to be uniform in character, of rather large size, with a very scanty rim of cytoplasm, and a trachychromatic round nucleus in which there is one central or two or three evenly distributed nucleoli. Some of the nuclei show peripheral chromatic thickening. Here and there are seen capillaries lined by swollen endothelial cells, containing a relatively large number of lymphocytes. Some of these capillaries have distinctly thickened walls. There is no other supporting structure among the lymphocyte-like masses. In size and character the cells of which the tissue is almost entirely composed have a strong resemblance to that of the germ-centre cells of ordinary lymph-gland. There are no cells of strikingly large size amongst these and no multinucleate cells.

Ref. : E. 3530. M.G.H. 08.79.

PRESENTED by Drs. Finley and Wolbach.

42.514² Mesenteric Glands. Hæmolymp Nodes in Acute Lymphatic Leukæmia.

Two pieces of mesentery containing a few much enlarged glands of dull reddish colour. The original outline of the glands is preserved. Many appear mottled externally. The cut surface shows an intense

engorgement, giving them a fleshy, and in parts hæmorrhagic, appearance.

D. B., male, aged 44. An Italian labourer. Admitted to the R.V.H. July 15th, dying two days later with purpuric symptoms and left hemiplegia.

P.M. Acute lymphatic leukæmia with purpura hæmorrhagica. Extensive hæmorrhages through the body.

Micro. Exam. The lymphatic follicular tissue has become increased so as to invade the whole organ. Some deeply congested areas occur in which an erythroblastic change occurs. The cellular elements are mesolymphocytic in type. Red blood cells are diffusely scattered through the organ.

Microphotograph (mounted beside specimen) shows parts of three bands of closely packed, very darkly stained cells of various sizes. A capillary vessel with thick walls and unduly full of leucocytes (stained black) is seen. The very variably sized cells in the tissue are immature atypical blood-cell parent cells, intermingled with small lymphocyte forms. This is characteristic of the structure of a hæmopoietic tissue in this disease.

See also Spleen, 43.514¹¹.

Ref. : E. 5207. R.V.H. 100.12.

PRESENTED by Dr. Gruner.

.515 Hodgkin's Disease.**42.515¹ Lymph-nodes in Hodgkin's Disease. (In two jars, *a* and *b*.)**

(*a*) The specimen consists of the neck organs dissected to show some enlarged glands by the side of the carotid artery. Their cut surface is dark in colour, and a focus of pale, necrotic-looking material is seen in one place. The glands about the bifurcation of the trachea are deep red in colour like hæmolympth glands with no evidence of caseation. The follicles at the root of the tongue are conspicuous, but not unduly large. The tonsils are not shown.

(*b*) A chain of greatly enlarged glands of deep-red colour. The cut surface shows that in many of them there are discoloured areas of peculiar form ; caseation seems to be taking place in some. All these glands are discrete, and there is no periadenitis.

Mrs. R. T., aged 76. Illness set in about ten weeks before death (Sept. 6, 1911), with widespread glandular enlargement, moderate pyrexia, 99° to 101°, and general malaise. There was a mass the size of a hen's egg in the right axilla, and one the size of a plum above the clavicle, and a solitary gland 1 cm. long in the right groin. On the left side the glandular enlargement was less marked, though palpable. On Sept. 23rd, as the axillary mass seemed softening, aspiration was performed, and blood and a few flakes of pus withdrawn. Slight improvement took place under tuberculin ; three inoculations 1 : 3000 to 1 : 3500 given. No cough. Nov. 7th, diarrhœa, with marked prostration, for the past ten days. Progressive enlargement of left supraclavicular, axillary, and suboccipital glands ; mass in right axilla slightly diminished. Œdema of left leg from intra-abdominal pressure. Abdomen distended, spleen palpable. Sat up in bed with difficulty during examination. Decubital pneumonia. Diarrhœa a marked feature. Differential count of white cells showed : polymorphonuclears, 50 per c.mm. ; small mononuclears, 40 ; large mononuclears, 5 ; eosinophiles, 1. Died Nov. 19, 1911. Clinical diagnosis : Lymphatic leukæmia or Hodgkin's disease.

P.M. Supraclavicular, inguinal, axillary, and retroperitoneal glands much enlarged, the latter 3 mm. to 4 cm. in diameter. Right axillary glands were removed intact and formed a chain 11 cm. long, discrete, easily separated, everywhere encapsulated, varying in size, on section pale greyish-red, some showing irregularly distributed yellowish-white foci. From left axilla a chain of 16 lymph-nodes was removed, not as large as those from right axilla, but of the same character, one gland presenting pale yellowish-white areas within its substance resembling areas of caseation seen in tuberculosis. Mesenteric glands not generally hypertrophied but firm and very pale. Lymph-nodes along the course of the internal iliac vein

hypertrophied, 1 to 3.5 cm. in diameter, of similar characters to those enlarged elsewhere. 100 c.c. of fluid in peritoneal cavity.

Bilateral broncho-pneumonia; acute ileocolitis; extensive intestinal ulceration; secondary anæmia; necrosis of submaxillary glands; lymphoid hyperplasia of axillary, mediastinal, retroperitoneal, and supraclavicular glands, Hodgkin's disease; tuberculosis of left apex of lung; chronic adhesive pleurisy and chronic localized peritonitis; ulcer of stomach; cholelithiasis; arterio-sclerosis.

Micro. Exam.—*Spleen*: The trabecular tissue is enormously hypertrophied, leaving mere islands of splenic tissue here and there. These islands are composed of closely grouped, moderately large, rounded cells with deeply staining cell-body and vesicular nucleus (atypical lymphoblasts). Cells with dusky cytoplasm and horseshoe nucleus also occur, along with plasma cells and very few scattered red cells. In some is a large central vessel with thick walls showing that the cell groups in question are really Malpighian bodies, while the strands of fibrous tissue is the sclerosed pulpar tissue with scanty red cells in the narrow vascular clefts permeating it.

Lymph-nodes: The capsule is a little thickened and sparsely infiltrated with small round cells. The capillaries of the gland are very conspicuously dilated. The connective-tissue septa are somewhat thickened. Ordinary follicular tissue is quite lost, the whole parenchyma being loose in texture, made of cells of various sizes, some lymphocytes, others mesolymphocytic, while many are almost lymphoblastic in form and size, though not presenting any characteristic arrangement.

Ref.: E. 4608. M.G.H. A. 10.202.

PRESENTED by Drs. von Eberts, Patch, and Rhea.

42.515² Gland in Hodgkin's Disease.

A greatly enlarged gland of a uniform creamy colour and homogeneous cut surface.

Male, aged 27. Ill for nine months with fever and swollen lymph-glands.

P.M. Combined tuberculosis and Hodgkin's disease. Changes in liver, spleen, pancreas, femur, and retroperitoneal lymph-glands.

Micro. Exam. The section shows very characteristic multinucleate cells, scattered irregularly through the tissue. They lie in large rounded groups of small round cells separated by rather broad bands of fibrous tissue.

See Specimens Nos. 41.515¹ and 43.515², and under Liver, Pancreas, and Kidney.

Ref.: E. 5097f.

PRESENTED by Prof. de Josselin de Jong, Rotterdam.

42.515³ Lymph-nodes in Hodgkin's Disease.

A piece of a much enlarged gland, showing the smooth regular contour of the surface, and the extensive pallor of the cut surface. Indications of distinct rounded pale masses separated by narrow bands of fibrous tissue can be observed.

No history.

See also Specimen No. 43.515³, and under Liver.

Micro. Exam. The normal lymphatic tissue is replaced by an irregularly formed granulation tissue, through which the typical giant cells of Hodgkin's disease are scattered. There is not much fibrosis.

Ref. : E. 4880c.

PRESENTED by Prof. de Josselin de Jong, Rotterdam.

42.515⁴ Lymph-nodes in Hodgkin's Disease.

The specimen shows a few subcostal and a group of greatly enlarged bronchial glands. They are regular in contour, smooth, discrete, and the cut surface is of a homogeneous, pale fawn colour, with one or two slender tracts of fibrous tissue traversing it.

Female, aged 23. Became ill in September 1907, with fever and cough. Von Pirquet negative. No tubercle bacilli in sputum. Marked anæmia. Died August 1908.

P.M. Many small and large tumours (Hodgkin's disease) in lungs, liver, spleen, lymph-glands, kidneys, and pancreas. Cavæ injected with tumour mass. No trace of tuberculosis.

Micro. Exam. The lymph-node structure is quite obscured, owing to loss of differentiation between follicular and pulpar tissue. Parts are replaced by a loose granulation tissue containing giant cells typical of Hodgkin's disease. There is a decided tendency to fibrosis.

See also Specimen No. 43.515⁴ and under Lung, Liver, Pancreas, and Kidney.

Ref. : E. 5096f.

PRESENTED by Prof. de Josselin de Jong, Rotterdam.

42.515⁵ Glands in Hodgkin's Disease.

Several groups of glands ; one mass envelops the aorta. Their contour is lost in adhesions which bind the individual glands together. One of the glands has been cut through, showing a perfectly homogeneous, pale, creamy surface.

F. H., aged 48. Married, 7 children, 1 abortion. Always healthy previous to onset of present illness. December 1910 complained of always feeling tired. Temperature elevated, liver and spleen enlarged. Died March 20, 1911.

P.M. Hodgkin's disease. Granulomata in liver, spleen, kidneys, pancreas, and retroperitoneal glands. Weight of liver 2,200 gm., of spleen 600 gm. No nodules in lungs.

Micro. Exam. There is a considerable amount of fibrosis in the form of interlacing bands, infiltrated with small round cells and multinucleate cells of characteristic form. This and the preceding cases should be compared by the student.

See also Specimen No. 43.515⁵, and under Liver, Pancreas, and Kidney.

Ref. : E. 5098e.

PRESENTED by Prof. de Josselin de Jong, Rotterdam.

.6 RETROGRESSIVE CHANGES.**.62 Degenerations.****.627 Calcification.****42.627¹ Calcification and Anthracosis of Bronchial Glands.**

A small, inky-black mass of tissue at the bifurcation of the trachea, and an enlarged calcified gland adjacent.

Old Museum specimen.

42.627² Calcified Gland.

An irregularly shaped calcareous mass of stony hardness, mottled with carbon deposit. It measures $3.1 \times 1.8 \times 1.2$ cm. It was obtained from within a mass of enlarged peribronchial glands.

Mrs. A., aged 52, was admitted to R.V.H. in May 1910, with signs of cholecystitis. The first illness had subsided without active treatment. She died two days after the gall-bladder operation.

P.M. Cholelithiasis, cholecystitis, and choledochitis. Fat-necrosis of pancreas. Obsolete tubercles of lung, bronchial, and mesenteric glands. Extreme degeneration of heart.

See also Specimen No. 24.627.

Ref. : E. 4764. R.V.H. 82.10.

PRESENTED by Dr. Gruner.

42.627³ Calcified Mesenteric Glands.

Two small, rounded, calcareous masses. The larger one is slightly lobulated. They are of pale ochre-yellow colour.

They lay embedded in fatty tissue.

Ref. : E. 5510c. P.H.I. Ap. 23.13.

PRESENTED by Dr. Kaufmann.

.63 Infiltrations.**.637 Anthracosis.****42.637¹ Anthracosis of Bronchial Glands.**

The bifurcation of the trachea, embedded in enlarged glands, which have a firm, fibroid structure and a mottled appearance due to the presence of inky pigment.

Old Museum specimen.

PRESENTED by Dr. Seaton.

.7 PROGRESSIVE CHANGES.**.71 Regeneration.****.711 Hyperplasia.****42.711¹ Hyperplasia of Periportal Glands in Obstructive Biliary Cirrhosis.**

Several enormously enlarged glands, of firm consistency, the largest measuring 7.5×5 cm.; cross section of another 4×4 cm. The outer surface is smooth. The cut surface is absolutely structureless to the naked eye.

M. V., aged 28. History of typhoid, with well-marked indications of old ulcerative cholecystitis and obliteration of the cystic duct.

P.M. Obstructive biliary cirrhosis of liver. Obliteration of cystic duct. Group of greatly enlarged glands in portal fissure about hilum of liver and in mediastinum.

Micro. Exam. Marked congestion; the lymphoid elements of the pulp seem relatively few, as the endothelioid plates and stroma cells show particularly well.

Ref.: R.V.H. 91.98. E. 114.

See also Specimen No. 37.39. Reported by Dr. W. W. Ford, *Amer. Journ. of Med. Sciences*, January 1901.

PRESENTED by Dr. Nicholls.

42.711² Hyperplasia of Lymph-nodes.

A concatenate mass of very large lymphatic glands, bound together closely by fibrous adhesions. The glands possess a pale brown colour, are of rounded shape, and regular contour. The cut surface of the largest mass is marked with numerous irregular caseous areas of pale brown colour. The intervening tissue is fawn in tint, and homogeneous.

E. 5163.

.712 Metaplasia.**42.712¹ Hæmolymp Glands.**

The specimen consists of the lower part of the trachea and the main bronchi, with portion of lung attached on the left side. Numerous lymphatic glands occur all around these parts, some being dark from carbon-infiltration, and others dark from intense vascularity. Note especially one riding on the left bronchus.

M. K., male, aged 20, was admitted to the R.V.H. in September 1910, suffering from septic endocarditis of six months' duration. There were scattered petechial hæmorrhages. The tonsils were hypertrophied. The spleen was enlarged.

Micro. Exam. The capsule is thickened. There are numerous pigment-bearing phagocytes throughout the tissues, and much blood through the gland substance, with active organization of the edges of the hæmorrhagic areas. Another section shows loss of arrangement in lymphoid tissue centres, increase of epithelial cells, and infiltration of many of the lymphatics with mast-cells and a few eosinophiles.

Ref. : R.V.H. 118.10. E. 4380a.

PRESENTED by Dr. Gruner.

.78 Malignant Tumours.**.786 Lymphosarcoma.****42.786¹ Lymphosarcoma of Cervical Glands Infiltrating Thyroid.**

A mass 12×5 cm. in diameter, embracing the root of the tongue and the anterior and lateral aspects of the trachea. It consists of greatly enlarged glands merged with the thyroid. A few moderately enlarged glands lie adjacent.

Micro. Exam. The tissue consists of small round mononuclear cells devoid of typical arrangement and supported by a minimum of connective tissue. In some parts of the section the cells are much more densely arranged than in others, and here the fibrous tissue is more abundant, giving the cell masses an appearance of lobation. Studied with an oil-immersion lens these small round cells are seen to be very similar one to another, having a very narrow rim of cytoplasm and a trachychromatic nucleus, within which are a few chromatic spots drawn out into short slender processes. The cells vary little in size, but here and there are one or two larger cells with large spherical nucleus staining less intensely. There are scanty relics of a delicate reticulum between the cells, and in relation to the reticulum are a few occasional cells of endothelial character. No multinucleate cells are to be seen. One or two eosinophile cells are to be observed.

Ref. : Old Museum specimen.

42.786² Glands. Lymphosarcoma.

The specimen consists of (1) the neck organs, supporting many large glands, loosely bound together by adhesions. They are oval, pale brown in colour, and the cut surface is fleshy and pale. (2) A mass enclosed in the mesentery, composed chiefly of closely packed, very much enlarged, lymphatic glands. These present similar characters to the above, but are somewhat larger. The peritoneal surfaces of the mesentery are surmounted by a covering of fine villous tags. (3) A huge mass of enlarged retroperitoneal glands. The cut surface is soft and marrowy, mottled with white streaks.

From the same case as 43.786¹, which see for full history and histology.

Ref. : E. 566. R.V.H. 62.99. *Journ. Med. Research*, 1901, pp. 249-57.

PRESENTED by Drs. Martin and Adami.

.79 Carcinoma.**42.79¹ Peritracheal Gland, showing Anthracosis as well as Carcinoma.**

The specimen consists of a piece of trachea and bronchi at the angle of which is a mass of enlarged glands which are infiltrated irregularly and diffusely with a new growth of white colour; permeating it is also some black pigment. There are pieces of enlarged gland which show definite nodules of new growth in addition to diffuse infiltration. Pigment is here less conspicuous.

Ref. : M.G.H. 65.95.

42.79² Carcinoma of Bronchial Glands.

The trachea with its bifurcation and the arch of the aorta embedded in an enormous mass of enlarged adherent glands, which on section are firm, not caseating.

Ref. : Old Museum specimen.

PRESENTED by M.G.H.

42.79³ Metastatic Cancerous Infiltration of Axillary Glands. (Petri dish Specimen.)

A group of glands embedded in fat; they are all of a size ($3 \times 1.6 \times 1$ cm.). They are discrete and firm in consistence; the cut surface of one shows a fleshy aspect, and its central part is streaked with red. The normal gland tissue seems to be entirely defaced. The capsule is infiltrated with blood.

Mrs. T., aged 49. Carcinomatous infiltration of axillary glands secondary to carcinoma of breast. Operation.

Ref. : M.G.H. S. 10.577. E. 4817.

PRESENTED by Dr. Rhea.

42.79⁴ Colloid Cancer with Calcification of Lymph-glands.

Two small, irregular masses of tissue, consisting of central opaque and creamy white substance, of hard consistence, enclosed in a transparent jelly-like material.

The primary growth was in the transverse colon.
For details see Spleen 43.79.
Ref. : R.V.H. 140.09. E. 4042.

PRESENTED by Dr. Klotz.

42.79⁵ Carcinoma of Mesenteric Gland spreading by the Lymphatics.

A small piece of intestine. Just at the root of the mesentery is a group of moderately enlarged glands, from one of which coarsely nodular strands radiate outward over the surface of the intestine, showing beautifully extension of the growth along the lymphatics.

Old Museum specimen.

PRESENTED by Dr. Adami from M.G.H.

42.79⁶ Pelvic Glands. Metastasis of Carcinoma.

A group of enormously enlarged glands, the largest 6×6 cm. across. The external surfaces are rough with adhesions. The cut surfaces show a trace of whorled structure, are of yellow colour, and appear to be breaking down in places. The cut ends of a thrombosed vessel are seen ; otherwise the tissue is non-vascular.

B. A., female, aged 22, was in hospital a month, suffering from pain in the left leg of knife-like character, also a yellowish foul-smelling vaginal discharge. Had felt ill for four years. Removal of a portion of tissue for diagnosis caused some hæmorrhage. A month later death occurred. There was a carcinoma of the cervix extending to the vagina, with metastases in the pelvic glands and peritoneal tissue.

P.M. A mass of glands occurred over the sacro-lumbar articulation, fixed to the underlying bone. The consistence was firm. Some yellowish fluid exuded here and there. A similar mass occupied almost the entire inner aspect of the left half of the pelvis and extended through the great sacro-sciatic notch to the soft tissues about the pelvis, involving the sacro-sciatic ligament.

Ref. : M.G.H. A. 07.204. E. 3242.

PRESENTED by Dr. Duval.

42.79⁷ Secondary Carcinoma of Inguinal Gland, with Central Breaking Down.

The specimen consists of half of an enlarged gland the size of a grape, indurated, having thickened walls and a central cavity and containing débris.

From a man, aged 71.

P.M. Primary lesion, epithelioma of penis.

Ref. : R.V.H. S. 164.96. E. 140.

PRESENTED by Dr. Bell.

42.79⁸ Enlarged Lymph-glands. Carcinoma.

A mass of enlarged glands situated along the abdominal aorta close to its bifurcation. The glands are mottled with pink areas of congestion and show scattered small caseous foci. They vary in size from a pea to a Brazil nut. A separate specimen mounted at the upper end of the jar has been cut through to show necrotic areas scattered through the gland substance, presenting the appearance of small abscesses.

McN., male, aged 50. Died of a fungating medullary cancer of the stomach with numerous secondaries in the liver, situated chiefly in the right lobe. He had only had symptoms three weeks before admission. For stomach see Specimen No. 34.79.

Micro. Exam. Shows the presence of tongue-like acini of spheroidal-celled carcinoma.

Ref. : E. 4378. R.V.H. 124.10.

PRESENTED by Dr. Adami.

.70 Cysts.**42.70¹ Cystic Enlargement of Bronchial Glands.**

The trachea to its bifurcation and the aortic arch at the origin of the great vessels. A cyst the size of an orange, with loculated interior and calcified walls, lies in the mediastinal tissue just anterior to the origin of the great vessels and to the left of the bifurcation of the trachea. Masses having a partly cystic, partly calcified interior lie on either side of the trachea, just below the larynx, the left the size of a pigeon's, the right of a turkey's egg. There is much gelatinous change.

Old Museum specimen.

PRESENTED by M.H.G.

43. SPLEEN

INTRODUCTORY

Anatomy. Weight of normal organ, 90–120 gm.; average size, $12 \times 8 \times 4$ cm. Possesses a fibrous tissue capsule, covered by a single layer of endothelial cells (peritoneal reflection). From this capsule *trabeculae*, consisting of fibrous, elastic, and muscular tissue, pass into the substance of the organ, forming a coarse network, in the meshes of which lie the pulp and the spleen follicles. The *follicles* are masses of adenoid tissue formed around terminal branches of the splenic artery. The pulp consists of blood-channels traversed by a fine network formed by flat endothelial cells and their processes; in the meshes of the pulp lie splenic cells, red corpuscles, leucocytes, macrophages, and a number of other cell-forms.

While the various types of morbid lesions that occur in other organs are recognizable in the spleen, the naked-eye appearances are apt to be so indefinite that microscopic examination is often the only satisfactory means of differentiation between them.

Changes in size. A review of the specimens shown in this section reveals striking changes in *size* as the most obvious source of variation in macroscopic appearance. All grades, from a very small organ (43.13¹, 43.61¹) the appearance of which is indistinguishable from that of an infantile spleen, through moderately large (43.325¹) and very large (43.513¹) to massive or giant spleens (43.514², 43.786¹), are demonstrated in the series. What may be looked upon as the natural size of the adult spleen is shown in specimen 43.17³.

It must be borne in mind that the mere measurements of the viscus are unimportant, whereas the *bulk* or volume is of significance. One spleen may be apparently large (in contour), but thin and plate-like, and yet be really smaller (less actual volume) than one that is shorter, narrower, but much thicker. Specimen No. 43.34¹ shows an instance of a rather small but bulky spleen.

With great increase in size, there goes a tendency to rounding of the contours of the organ. If notches be present they are exaggerated; the presence or absence of these may be evidence of excessive enlargement of the splenic substance. Many of the specimens shown here are devoid of notching (43.222¹, 43.61⁵). Shrinkage of the organ is usually manifested by wrinkling of the capsule (43.61³) rather than by an absence of notching.

The macroscopic evidences of increase in splenic tissue then are : (1) increase in total size of the organ ; (2) increase in bulk ; (3) tense-ness of the capsule ; (4) rounding of edges ; (5) exaggeration of notches ; (6) bulging outwards of the cut surface of the viscus ; (7) increase in weight.

It will be borne in mind that increase in size may be due either to engorgement (43.351³) or to an actual increase of tissue. The latter may consist in an increase of pulp tissue (43.343¹) or it may depend on the presence of deposit of tumour or granulomatous masses (43.79², 43.361⁷). In this connexion attention must be drawn to the existence of physiological variations in size of the spleen, which may be considerable in degree. With the exception of the giant spleens, and such specimens as 43.513¹, 43.513³, and 43.39¹¹, which would not show cyclical changes of size because of the inability to contract in the one case, and because of the restraining inflammatory tissue enclosing the viscus in the others, each of the specimens on the shelves may be looked on as an instance of an organ suddenly arrested and fixed at the moment of having attained that particular size, which would have changed had the organ lived.

[*Examples of Enlargement of the Spleen :*

(a) Moderate :

Early passive congestion	43.222 ³
Acute splenitis	43.34 ¹
Typhoid	43.351 ^{1,3,4,5,6}
Malignant endocarditis	43.343 ^{1,2}
Pneumonia	43.344 ¹
Cerebrospinal meningitis	43.348 ¹
Miliary tuberculosis (acute)	43.361 ²
Syphilis	43.372 ¹
Tuberculosis (subacute)	43.361 ⁷
Amyloid	43.625 ³

(b) Still larger (intermediate to Splenomegaly):

Spleen in cirrhosis of liver (size due to passive congestion plus irritation from noxa producing liver condition)	43.721 ⁻²
Spleen in Hodgkin's disease	43.515 ¹
Spleen in lymphatic leukæmia	43.514 ¹⁰
Spleen in secondary sarcoma	43.786 ²
Spleen in syphilis	43.372 ²
(Also earlier stages of giant spleen)	

(c) Giant spleen (Splenomegaly):

Malaria	43.376 ¹
Splenic anæmia, Banti's disease, &c.	43.513 ¹
Splenomyelogenous leukæmia	43.514 ²
Lymphosarcoma	43.786 ¹
Lymphatic leukæmia	43.514 ¹¹

Examples of Reduction in size of the Spleen:

Congenital aplasia	43.13 ¹
Passive congestion (late stage)	43.222 ⁵
Senile atrophy	43.61 ^{1,2,5}
Hyaloserositis of capsule	431.39 ²⁰
	—Ed.]

Alterations in shape are rarely met with (43.79²). 43¹ shows a long thin spleen, but this is not human.

Alterations in number are not infrequent. One or more accessory spleens may be found in various situations. See Specimens 43.17¹⁻⁴. The existence of such rounded masses or miniature spleens is of interest in that there is evidence pointing to their being formed during life, as a hyperplasia. (For microscopic appearances of accessory spleens, see under Specimen No. 43.17⁴.)

Changes of colour are striking. All shades from pale pink (43.222⁵) to deep red (43.351⁵) and purple or slate (43.514¹³) indicate varying degrees of congestion, and are best seen in the unopened organ. The cut surface may show a similar range of colours (excluding the slate-greys), though these are less easily preserved in a museum specimen. Other colours, creamy (43.513³), yellow (43.61¹), pale greys (43.514³), ochre (431.39¹¹), fawn (431.39²³), brown (43.514¹), are met with where the capsule is changed, or where a new deposit such as tubercle or tumour-formation occurs. The most obvious colour-changes are those seen in the collection of infarcts (43.26¹⁻²⁹) exhibited in the series. Here the varying change of colour depends partly on circulatory conditions in the infarcted area, and partly on the process of repair, the very old forms being chalky-white with a brilliant yellow contour (43.26²⁰), and perhaps a vivid but very fine line of red at the extreme edge of the area (43.26²³). The infarctions, as dealt with fully in the *Text-book of Pathology*, by Drs. Adami and McCrae, are of various types, single, multiple, white, red, recent, old, calcifying, breaking-down, &c., and each of them is represented in the series herein referred to. The marked variability in the contour of the area will be noticed, some being sharp and clean-cut, while others have very irregular outlines rich in sinuosity.

The specimens of infarcts are arranged thus: Beginning with a definite red infarction (43.26¹) of very dark uniform colour, we pass to 43.26⁴ whose centre is white, and then to 43.26⁵⁻¹², which are all characterized by a slate-grey centre and very clean-cut outline. This change of colour is indicative of autolytic breaking-down of the dead splenic substance. The gross result of this is such a degree of softening (especially noticeable after the cut surface has been standing in the jar) as to be difficult to differentiate from the suppurating

infarcts shown in 43.325^{1,2}. It will be noticed that the breaking-down is more of a honeycomb form in 43.325², which forms a useful guide to the diagnosis. Passing on from these types, we come to 43.26²⁰⁻²⁴, whose cut surface shows a very homogeneous, almost cheesy appearance, while the sharp contour and retracted edges mark the advanced age of the lesion. Chalky-white infarcts are shown in 43.26²⁵⁻²⁷. The interesting variant described as arteriosclerotic in origin is well shown in 43.26²⁸, where three broad grey bands traverse the organ without a very clear line of demarcation. Lastly, 43.26^{29,30} afford a convenient transition from the 43.26 series to the suppurating infarcts (43.325¹⁻³) already referred to.

Inflammations. *Acute splenitis* is indicated to the naked eye by enlargement and intense deepening of colour. While the diagnosis of this condition is usually deductive, there can be no doubt as to its existence in such specimens as 43.324¹, where the cut surface shows a number of foci of deep red colour, rather clearly demarcated from the surrounding pale pulp. 43.324² is an example in which the whole organ is very deep in colour. Several of the specimens grouped under the infections—streptococcic 43.343¹, meningococcic 43.348¹, colon group 43.357¹, typhoid 43.351¹⁻⁵—are also examples of acute splenitis; when such specimens are fresh and in the hand they are conveniently referred to as diffuent or febrile spleens. Sometimes these infective conditions are associated with abscess formation, 43.351^{4,5} being interesting examples (due to infarction) from cases of typhoid fever. 43.325³ also exemplifies suppurative inflammation (abscess), but it is not clear whether this is *de novo* or a later change in a previous infarct. The sharp definition of the lesion is strongly in favour of the latter view. On the other hand, 43.325⁴ is a good example of multiple foci of suppuration disseminated through the organ.

Chronic inflammatory hyperplasia is shown in 43.372^{1&2}, 43.376¹, 43.513¹⁻³, and manifests its existence in the gross specimens by increase in size (43.376¹), change of colour (43.372¹), or abundance of fibrillar strands through the cut surface (43.513¹). To be sure of the diagnosis, however, one must call in the aid of the microscope.

Inflammatory changes in the capsule are demonstrated in the series 431.39¹⁻³ (perisplenitis) and 431.39¹⁰⁻²³ (hyaloserositis and 'lamellar fibroma'). One instance of suppurative perisplenitis (431.325¹) serves to demonstrate the link between this condition and general plastic peritonitis. Thickening due to tubercle is shown in 431.361¹⁻².

Tuberculosis. The series 43.361¹⁻²⁰ shows different forms of this

disease, beginning with the miliary forms of successively lessening degree of acuteness (43.361¹⁻¹¹) and passing on to the obsolete forms 43.361¹⁵⁻¹⁷. 43.361² presents the characteristic change met with in bovine tuberculosis, and here there is enormous thickening of the capsule and almost cartilaginous appearance of the cut surface of the tubercles. The acute miliary forms appear as a peppering of the cut surface with minute white specks hardly any larger than Malpighian bodies. The subacute forms present larger lesions which often show a brilliant red contour. 43.361⁸ shows much larger tubercles whose centres are breaking down in a crateriform manner. The appearance in 43.361¹⁰ is rather different in that the lesions vary very greatly in size. The obsolete character of 43.361¹⁵⁻¹⁷ is shown by the dead-whitish colour and clear definition without any limiting line. 43.357¹ is a case of tuberculosis which should fit in between 43.361¹⁰ and 43.361⁸, but does not show the tuberculous lesions very well owing to riddling of the whole organ with the spaces produced by *B. aerogenes capsulatus*, and it is therefore classed under lesions due to this organism.

Degenerations. Reference has been made to the small spleens 43.61¹⁻⁶, where the diminution in size is due to atrophy of the organ as a whole. The four specimens 43.625¹⁻⁴ illustrate different degrees of amyloid disease from a diffuse change ('bacon spleen'), 43.625¹, through more discrete and larger foci, to 43.625⁴, where the individual foci of amyloid change are merely conspicuous against the remaining splenic tissue, appearing almost hyaline.

Progressive Changes. Specimens illustrating these changes are grouped under 43.72¹⁻⁶, 43.786^{1,2}, 43.78¹, and 43.79¹⁻³, but the fundamental nature of the change may in many cases be misunderstood if the student takes the idea that these are the only instances in the whole collection. It is hard to draw the line between 43.72² (enlargement in cirrhosis of liver and Banti's disease) and 43.513¹, and even 43.343¹ (acute splenitis of streptococcus origin) may be placed in the same category because the hypertrophy must be due in each case to an overgrowth of the pulp tissue, and as far as the naked-eye character goes there is no difference between hypertrophy, hyperplasia, and metaplasia. Without an analysis of the clinical and anatomical factors (aided by the microscope) no one could say that 43.72² is not really more correctly placed under 43.513 (Banti's disease).

The new growths are classified as primary and secondary, the latter being more common. The enormous size of 43.786¹ (primary lymphosarcoma) is of interest, especially if one attempts to realize the weight that it would have within the body. The secondary deposits of carcinoma, 43.79¹⁻³, are of comparatively little interest.

Their identification with the naked eye would depend on the same rules as apply to these tumours in general.

Cysts. These are usually small and difficult to demonstrate in a mounted specimen. They are usually intracapsular or sub-capsular, and lined by lymphatic endothelium (43.70¹).

Rupture. 43.819¹ is an interesting example of this condition; the more so as the patient recovered.

Pernicious anæmia. The two specimens (43.516^{1&2}) taken from cases of this disease show merely the relative increase of fibrous tissue and the pale maroon colour of the splenic substance. The more specific changes in such a case would be found with the microscope, and are described in the Catalogue under the specimens quoted above.

Leukæmias. There is little to be said on this subject in connexion with the gross specimens. In all varieties of the disease there is a great enlargement, and it is not possible to see with the naked eye whether the change is dependent on the pulp or the follicular tissue. (Note that 43.514¹ is probably much shrunken in consequence of the method of preservation.) In each case the points to notice are: great bulk, prominent notching, perisplenic areas, occasionally infarcts.

It is important for the student to realize that leukæmia is never a disease of the spleen as such; it is a system-disease of the hæmopoietic organs, and the enlargement of the spleen is only part of a morbid process disseminated widely throughout the whole body. Consequently none of the specimens of the series 43.514¹⁻¹³ can be looked upon as representative of even the *main* lesion of the disease.

Once this is understood, it becomes easy to see that 'lymphatic' leukæmia may provide a spleen as large as 43.514¹³.

The word 'lymphatic' in this connexion is correctly employed to represent two features: (a) the existence of immature white cells of the lymphoid series in the blood, (b) excessive formation of immature lymphocytic cells in every blood-forming tissue in the body. Frequently the lymph-nodes constitute the main source of lymphoblasts (parent cells of lymphocytes) even in disease, hence they are the most conspicuously enlarged in lymphatic leukæmia. Nevertheless, the Malpighian follicles of the spleen are very important centres of lymphoblastic activity, and are likely to participate in the morbid process. In such a case this viscus becomes more and more enlarged.

Again, in 'myeloid' leukæmia there are the following two features: (a) existence of immature white cells of the myeloid (or polymorphonuclear leucocyte) series, myeloblasts, myelocytes,

&c. ; (b) excessive formation of immature myeloid cells. . . Wherever there are blood-formative cells capable of developing into myelocytes, they assume this character actively. The bones are the most likely centres of this tumour-like overgrowth of myelocytoid cells, but the pulp of the spleen and lymph-nodes is equally potent in this direction. Hence the frequency with which enlargement of the spleen is noted in this disease, and the apparent paradox that lymph-nodes may be enlarged in 'myeloid' leukæmia.

The difference between this conception of the disease and that in vogue earlier is at once evident. Formerly, myeloid leukæmia was regarded as a disease of the bone-marrow, splenic leukæmia as one of the spleen ; the perplexity of a splenic case giving a 'myeloid' blood-picture seemed insuperable. As soon as it was realized (1) that leukæmia is a proliferative process set up by intoxication of some sort, simulating malignant disease in certain interesting ways ; (2) that this process may run on either myeloid or lymphatic lines ; (3) that each group of blood-forming organs contains myelo- or lympho-potentialities—these apparent paradoxes, e.g., that a spleen may be enormous and yet belong to a case of lymphatic leukæmia, ceased to be strange.

Hodgkin's disease. The series of specimens 43.515¹⁻⁵ taken from cases of Hodgkin's disease, exemplify two types of lesion in the spleen, the first one being diffuse (no nodules), while the second exhibits numerous discrete whitish masses simulating new growth, and classifiable macroscopically with the subacute tuberculoses (cf. 43.361¹⁷). The disease is more familiar in connexion with the lymph-nodes, and is best discussed under that heading (see 42.515¹⁻⁶).

DETAILED CONTENTS OF SECTION

43. SPLEEN

- Abscess 43.351⁵; 43.315⁴; 43.364¹ (multiple).
- Accessory spleen 43.17¹⁻⁴; 43.222⁴; 43.324¹; 43.351¹;
43.72¹; 43.361¹.
- Acute yellow atrophy, Spleen in 43.531¹.
- Acute splenitis 43.34¹; 43.344¹; 43.351²; *see also*
Hæmorrhagic splenitis.
- Adhesions :
- Bands 43.514¹.
- Dense 43.361¹¹; 43.1.39².
- Old 43.1.39¹.
- Shaggy 43.222⁵; 43.26¹¹; 43.26²⁹; 43.26²⁵;
43.325²; 43.376¹; 43.361⁸; 43.516³;
43.61; 43.72⁶; 43.786¹; 43.1.325¹;
43.1.361².
- Shreds of lymph 43.222²; 43.26⁶; 43.26⁷; 43.26²²; 43.26^{24,26};
43.351¹; 43.513²; 43.514²; 43.61³;
43.625⁴; 43.72¹; 43.1.39¹; 43.1.39^{12,13};
43.1.796¹.
- Amyloid disease 43.364¹; 43.625¹⁻⁴.
- Animals 43¹ (cat); 43.361²⁰ (cow).
- Anomaly of shape 43¹; 43.26⁷.
- Appendicitis, Spleen in 43.34¹.
- Aplastic Anæmia, Spleen in 43.516².
- Atrophy of spleen 43.61¹⁻⁸ (⁴⁻⁷ are senile).
- Bacillus aerogenes capsulatus infection 43.357¹.
- Banti's disease 43.513^{1,2,3}.
- Blood-channels, Dilated; *see* Histological characters.
- Calcareous nodule in 43.61⁸.
- Carcinoma of 43.79¹⁻³; 43.1.796¹.
- Cat, Spleen of 43¹.
- Cerebrospinal fever, Spleen in 43.348¹.
- Cirrhosis of liver, Spleen in . 43.513³; 43.72^{1,3,4}.
- Comparative anatomy of spleen; *see* Cat, Cow.
- Congestion :
- Focal 43¹; 43.26²; 43.325⁴; 43.344¹.
- Passive 43.222¹⁻⁵; 43.26⁷; 43.26²⁴; 43.325².
- Cow 43.361²⁰.
- Cysts 43.70¹; 43.1.70^{1,2}.
- Endocarditis, Malignant 43.26^{3,6,8,21,22}; 43.325³; 43.343¹; 43.343³.

- Erythræmia 43.512¹.
- Febrile spleen; *see under* Size.
- Fibrosis of spleen 43.222^{2,3,5}; 43.372¹ (syphilis); 43.513³;
43.516² (histological); 43.614⁻⁸;
43.72^{5,6}; 431.39^{11,21,22}.
- Gaucher's splenomegaly 43.513¹⁰.
- Glanders, Spleen in 43.364¹.
- Hæmorrhagic splenitis 43.324¹⁻³.
- Hæmorrhagic mottling 43.222¹; 43.26²⁵; 43.324¹⁻³; 43.34¹;
43.351⁶ (typhoid); 43.361¹¹; 43.372¹;
43.72⁶; 43.819¹.
- Histological characters of spleen :
- Blood-channels, Dilated 43.222²; 43.26^{2,29}; 43.324¹⁻³; 43.34¹;
43.344¹; 43.372²; 43.513²; 43.515¹⁻³;
43.516¹⁻³; 43.531¹; 43.61⁶⁻⁸; 431.39¹.
- Fibrosis of pulp; *see under* Fibrosis of spleen.
- Malpighian bodies, q. v.
- Pulp-tissue :
- Congestion of 43.17⁴; 43.222⁴; 43.26⁷; 43.348¹; 43.351⁶.
- Crystals in 43.325³.
- Foci inflammatory cell infiltration 43.324¹⁻².
- Hæmorrhagic areas in 43.361²; 43.372².
- Hyaline change in 43.372².
- Lymphoid structure 43.26¹⁰; 43.514¹⁰.
- Necrotic focus in 43.351⁵.
- Pigment in 43.325³; 43.515^{3,5}; 43.72⁵.
- Pigmentophages conspicuous 43.348¹; 43.361¹⁷; 43.376¹; 43.514¹³;
43.515⁵; 43.614^{6,8}; 43.625³.
- Pulpoid change universal 43.514¹¹.
- Reticulum conspicuous 43.222²; 43.26²⁸; 43.361¹⁷; 43.513^{1,2};
43.515¹; 43.516¹; 431.39^{11,20}; *see*
also Fibrosis of spleen.
- Trabecular tissue, hyaline 43.324¹; 43.372²; 43.514¹⁰; 43.515^{1,3};
43.516²; 43.72⁵.
- Hodgkin's disease, Spleen in 43.515¹⁻⁵.
- Hyaloserositis 43.222⁴; 43.72¹⁻³.
- Multiple foci 43.26¹²; 431.39¹⁴.
- Single large patch 43.325¹²; 43.361²⁰; 43.513^{1,3}; 43.614¹;
431.361²; 431.39^{10-13,20-23}.
- Infection with *Bacillus aerogenes capsulatus* 43.357¹.
- Infarcts :
- Hæmorrhagic 43.26^{2,3}.
- Multiple 43.26^{1-5,6,7,8,9,10,25,28,29}; 43.361¹⁶; 43.343²;
43.514^{2,3}; 43.516²; 43.625¹; 43.26^{1,7,9,25};
43.351⁴.

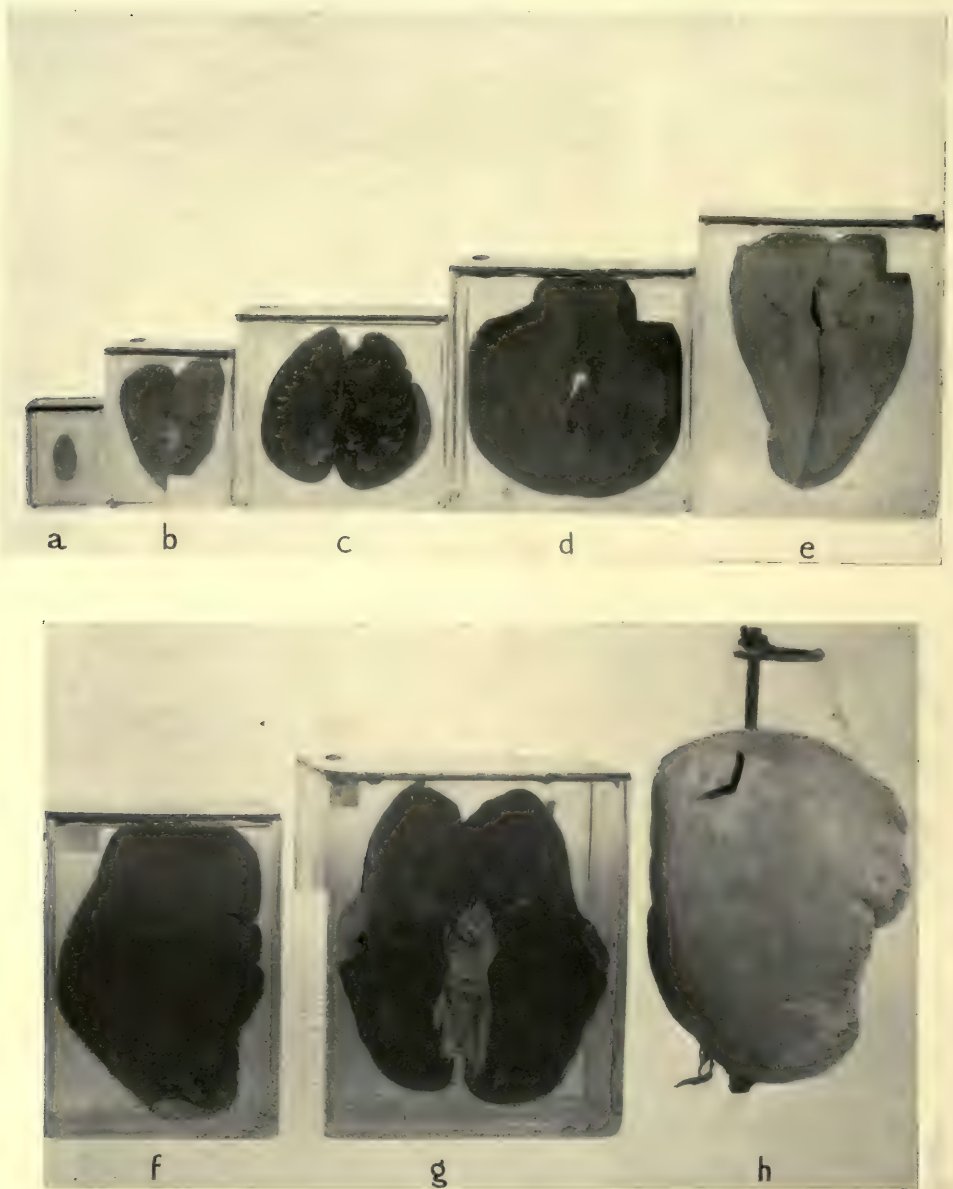
Old	43.26 ^{11,21,24} ; 43.351 ⁴ .
Pale	43.26 ²⁰ ; 431.39 ²⁰ .
Softening	43.514 ⁴ .
Suppurating	43.325 ^{1,3,4} (multiple) ; 43.343 ¹ .
White	43.26 ^{4,7,12,22,23,24,25,26,27,28} .
Lamellar fibroma	431.39 ²¹⁻²² .
Large spleen ; <i>see under</i> Size.	
Leukæmia, Spleen in	43.514 ¹⁻¹³ (¹⁰⁻¹³ are acute lymphatic).
Lymphoma of spleen	43.516 ² .
Malpighian bodies :	
Absent	43.222 ⁴ ; 43.324 ² ; 43.325 ³ ; 43.344 ¹ ; 43.351 ² ; 43.513 ³ ; 43.514 ¹ ; 43.514 ^{10,11,13} ; 43.61 ⁵ .
Hyaline change in	43.17 ⁴ ; 43.515 ¹ ; 43.516 ³ .
Central vessel of :	
Fibrotic	43.513 ³ .
Hyaline	43.324 ³ ; 43.361 ¹⁷ ; 43.61 ⁶ ; 43.625 ¹⁻⁴ (amyloid) ; 431.39 ¹ .
Tortuous	43.222 ^{2,4} ; 43.515 ¹ ; 43.79 ³ .
Necrotic change in	43.348 ¹ .
Numerous	43.17 ⁴ ; 43.324 ¹ ; 43.516 ³ ; 43.61 ^{1,8} ; 43.79 ³ .
Size :	
Large	43.26 ^{10,12} ; 43.34 ¹ ; 34.351 ¹ ; 43.361 ^{1,20} ; 43.514 ¹² ; 43.515 ³ ; 43.61 ⁴ .
Medium	43 ¹ ; 43.17 ² ; 43.222 ¹ ; 43.222 ⁵ ; 43.26 ⁷ ; 43.515 ¹ ; 43.516 ³ ; 43.72 ^{4,5} .
Small	43.17 ⁴ ; 43.222 ²⁻⁴ ; 43.26 ² ; 43.324 ^{1,3} ; 43.325 ⁴ ; 43.351 ⁶ ; 43.372 ³ ; 43.513 ^{1,2} ; 43.516 ^{1,2} ; 43.61 ^{7,8} ; 431.325 ¹ ; 431.70 ¹ .
Passive congestion	43.222 ¹⁻⁵ ; 43.26 ⁷ ; 43.26 ²⁴ ; 43.325 ² (late).
Perisplenitis :	
Bands	43.514 ¹ .
Chronic	431.39 ^{1-2,10-14,21,23} .
Lamellar	431.39 ^{21,22} .
Suppurating	431.325 ¹ .
Tuberculous	431.361 ¹⁻² .
Pernicious anæmia, Spleen in	43.516 ¹⁻³ .
Plague, Spleen in Bubonic ¹ .	43.359.
Pneumonia, Spleen in	43.324 ² ; 43.344 ¹ .
Pulp-tissue ; <i>see under</i> Histological characters.	
Purpura	43.514 ^{10,11} ; 43.61 ⁸³ ; 43.786 ² .
Rupture of	43.819 ¹ .
Sago spleen	43.625 ¹⁻⁴ .

Sarcoma	43.78 ¹ ; 43.786 ¹⁻² .
Senile spleen	43.361 ¹⁵ ; 43.614 ⁻⁷ .
Septicæmia, Spleen in	43.343 ¹ .
Shape, anomalous	43 ¹ ; 43.26 ⁷ .
Size :	
Large	43.364 ¹ ; 43.372 ² ; 43.516 ² ; 43.625 ¹ ; 43.72 ^{1,3,4,5} ; 43.79 ¹ .
Febrile	43.26 ⁹ ; 43.324 ² ; 43.34 ¹ ; 43.343 ¹ ; 43.344 ¹ ; 43.348 ¹ ; 43.351 ¹ ; 43.351 ^{3,5,6} .
Giant	43.376 ¹ ; 43.513 ¹ ; 43.514 ¹⁻¹³ .
Passive congestion	43.26 ²⁴ .
Tuberculous	43.361 ⁷ .
Miniature	43.13 ¹ ; 43.26 ¹ .
Small	43.26 ^{4,5,21,27,30} ; 43.361 ^{1,15} ; 43.61 ¹⁻⁸ ; 431.325 ¹ ; 431.39 ^{12,14,22} .
Small febrile	43.26 ²⁵ ; 43.351 ⁴ .
Splenectomy	43.72 ⁶ ; 43.819 ¹ .
Splenomegaly, Primary :	
Banti's	43.513 ¹⁻³ .
Gaucher's	43.513 ¹⁰ .
Splenitis, Acute	43.34 ¹ ; 43.344 ¹ ; 43.351 ² .
Spots on,	
Pin-point	43.222 ^{2,4} ; 43.361 ⁴⁻⁶ ; 43.516 ² ; 43.72 ³ ; 43.79 ⁹ ; <i>see also</i> Hyaloseritis.
Yellow	43.26 ¹ ; 43.786 ² ; 43.79 ³ .
Syphilis, Spleen in	43.372 ¹ .
Trabecular tissue; <i>see under</i> Histological characters.	
Tuberculosis of	43.361 ^{8,10,16,17,20} ; 43.515 ² .
Miliary	43.26 ²⁴ ; 43.357 ¹ ; 43.361 ^{1,2,3-6,11} .
Obsolete	43.361 ¹⁵ ; 431.361 ^{1,2} ; Tbc.* 46 and 47; 43.361 ⁷ ; Tbc.* 48.
Typhoid, Spleen in	43.26 ²⁵ ; 43.325 ¹ ; 43.351 ¹⁻⁶ .

* Tbc. 46, 47, 48 refer to the collection of Tuberculosis in the General Pathology Section of the Museum.



PLATE VI



VARIATIONS IN SIZE OF SPLEEN IN DIFFERENT CONDITIONS

- a.* Congenital Hypoplasia (43.13¹).
- b.* Passive Congestion, late stage, with small infarct (43.26¹).
- c.* Passive Congestion, earlier stage than *b* (43.222³).
- d.* Acute Splenitis in Typhoid (43.351¹).
- e.* Enlargement of Spleen in Cirrhosis of Liver (43.72³).
- f.* Splenomegaly in Lymphatic Leukæmia (43.514¹²).
- g.* Splenomegaly in Banti's Disease (or Malaria ?) (43.72⁶).
- h.* Splenomegaly in Myelogenous Leukæmia (43.514²).

43. SPLEEN

CATALOGUE*

Anatomical Series

.1 ANOMALIES.

.12 Malformations of Incomplete Development.

See 43.13¹.

.13 Reduction in Size. (Hypoplasia.)

43.13¹ Miniature Spleen.

An abnormally small organ, measuring only 4.5 × 2 cm. The notches are indistinct, but the shape is otherwise natural. The vessels entering the hilum are very large.

From a man of about 40, in whom no other anomalies of the lymphoid structures were observed. The cause of death was unknown.

Ref.: Dissecting Room.

PRESENTED by Dr. J. G. McCarthy, 1902.

.14 Reduction in Number.

None in this series.

.15 Persistent Fœtal Structures.

None in this series.

.16. Excess in Size.

None in this series except as a result of post-natal disease.

* For abbreviations used in this Catalogue, see page xviii.

.17 Excess in Number.**43.17¹ Multiple Accessory Spleens.**

Five flattened round bodies, of different sizes, the largest 2 cm. in diameter, and the smallest 0.6 cm. The surface in each case is wrinkled and opaque.

Ref. : E. 3122.

PRESENTED by Dr. Klotz.

43.17² Accessory Spleen.

Half of a spleen with a piece of the gastrosplenic omentum. A small round accessory organ, measuring $2 \times 2 \times 1.5$ cm., covered with areolar tissue, is attached to the omentum at a distance of 1.5 cm. from the spleen. The capsule is thin and has a smooth surface resembling that of the spleen proper. Its consistence is rather soft, and the cut surface shows the Malpighian bodies distinctly.

PRESENTED by Dr. Adami.

43.17³ Accessory Spleen.

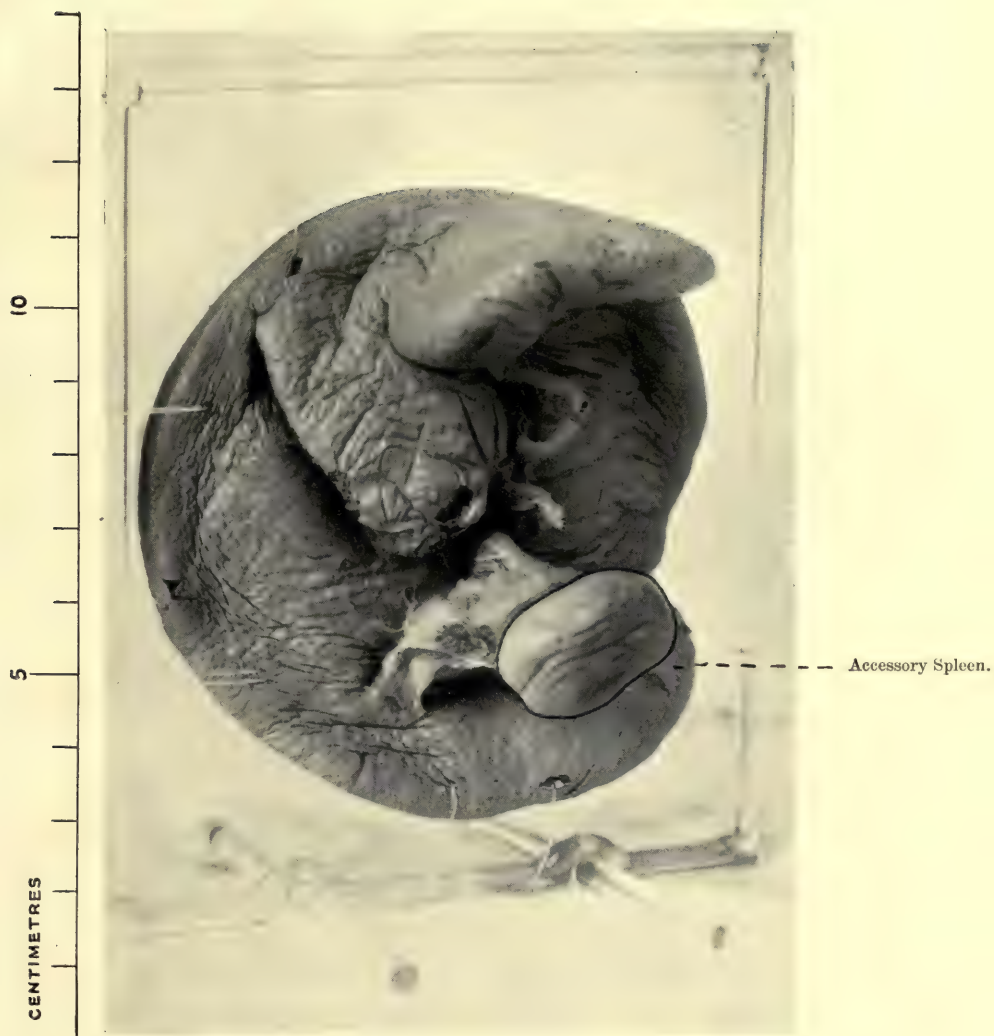
Spleen with tail of pancreas, near which is an accessory organ, measuring $2.5 \times 1.5 \times 1$ cm., which lies beneath the tail of the pancreas. The surface is wrinkled, and has the same appearance as that of the spleen itself, which is of normal size ($8 \times 8 \times 3$ cm.). The cut surface shows no characteristic feature.

A. J., female, aged 53. The accessory spleen was situated in a fold of the omentum, rather to the inner side of the organ, near the tail of the pancreas. No other abnormalities noted.

Ref. : R.V.H. 32.99. E. No. 540.

PRESENTED by Drs. Bell and Nicholls.

PLATE VII



43.17³ ACCESSORY SPLEEN, ATTACHED TO ORGAN
OF NORMAL SIZE



43.17^a Multiple Accessory Spleens.

A number of small spleens, measuring respectively $5.5 \times 4.5 \times 2$ cm.; $3.4 \times 1.6 \times 2.4$ cm.; 2.5 cm.; 2 cm.; 2 cm.; 1.7 cm.; 1.7 cm. The five last named measured the same in each direction of space.

These are all red in colour and connected together by a fatty mesentery. Each structure presents the appearance of a natural spleen, the capsule being a little wrinkled, while the cut surface is dark in colour. The Malpighian bodies are easily seen as minute white specks. The trabecular tissue is moderately conspicuous.

Mrs. M. L., aged 25. Admitted comatose. Died of acute encephalitis, pneumococcus infection.

P.M. Acute cerebro-spinal meningitis and encephalitis, thrombosis of left lateral sinus. Calcified plaques in arachnoid of spinal cord (see Specimen No. 72.627¹). Oedema and congestion of lungs. Multiple spleens, bilateral hydronephrosis and hydro-ureters, anomalous attachment of intestines.

Micro. Exam. Shows numerous moderately large Malpighian bodies. The intervening pulp-tissue is congested, poor in pulp-cells, and rather scanty in amount. Some Malpighian bodies show hyaline degeneration. The trabecular tissue is moderately conspicuous.

Ref. : M.G.H., A. 10.97 ; E. 4515.

PRESENTED by Dr. Rhea.

.2 CIRCULATORY DISTURBANCES.**.22 Congestion or Hyperæmia.****.222 Passive Hyperæmia.****43.222¹ Spleen in Passive Congestion of Cardiac Origin.**

A spleen of normal size, $12 \times 8 \times 5$ cm., with a smooth, tense surface, free from adhesions and showing normal notching. At each pole the capsule shows extensive hæmorrhagic mottling. The cut surface is dark red in colour and shows the trabeculæ very distinctly. The Malpighian bodies are distinct but normal.

E. L., male, aged 62, was admitted suffering from cardiac failure following old aortic stenosis. The patient was born in France, but was in Canada for thirty years; had never done heavy physical work.

P.M. Aortic stenosis, chronic myocarditis, hyaloseritis of liver, cholelithiasis, chronic interstitial nephritis.

Ref. : R.V.H. 54.06. E. 1567.

43.222² Passive Congestion of Spleen in Cardio-renal Disease.

Half of an enlarged spleen (15×9 cm.), whose capsule is more opaque than usual (slate-grey) and slightly wrinkled. The surface everywhere is dotted with white pin-point elevations. The cut surface is pale (loss of colour) and almost homogeneous, though close inspection reveals a number of small Malpighian bodies. There is an increase in the trabeculæ. The cut surface bulges outward.

Mrs. C. B., aged 64, was admitted for the effects of cardiac failure, which had existed for five months and steadily progressed.

P.M. Cardio-hepato-renal disease with extreme ascites, œdema of lungs, bronchitis, dilated hypertrophied heart, general fatty arterio-sclerosis, cirrhosis of liver, chronic cholecystitis, perisplenitis, ascites, adiposity, chronic interstitial nephritis.

Micro. Exam. The capsule is thickened, but the trabeculæ are not. The Malpighian bodies are unaltered in number. The central vessel is thickened and tortuous. The reticulum is conspicuous and the blood-vessels are engorged.

Ref. : R.V.H. 3.11. E. No. 4573.

PRESENTED by Dr. Gruner.

43.222³ Spleen. Early Passive Congestion in Acute Broncho-pneumonia.

The spleen of a child laid open; one-half has a finely puckered surface, the other half is roughened with long threads of lymph. The cut surface shows increase in the amount of fibrous tissue, the trabeculæ being very conspicuous. The colour is very dark. The Malpighian bodies are not visible.

S. C., male infant, aged 6 months. Cough and diarrhœa developed July 13, 1906. Admitted to R.V.H. August 8th, almost moribund. Died next day.

P.M. Acute broncho-pneumonia in both lower and in right upper lobes. Empyema and interstitial emphysema. Acute muco-purulent bronchitis. Fatty infiltration of liver. Passive congestion of spleen.

Micro. Exam. Spleen congested so that section appeared to be made up of numerous lacunæ. The dilated blood spaces were lined with endothelium.

Ref. : E. 4029. R.V.H. 107.06.

PRESENTED by Dr. Keenan.

43.222⁴ Spleen. Passive Congestion in Chronic Heart Disease.

Half of a slightly enlarged spleen $15 \times 7 \times 5$ cm., weight 345 gm., with very much rounded edges, slaty colour, and firm consistence. There are spots of hyaloseritis on the outer surface. The cut surface shows little differentiation of structure, and is very dark in colour. Malpighian bodies cannot be made out. The trabeculæ are moderately conspicuous. The organ was firm.

Mrs. M. B., aged 38, was admitted to the R.V.H. on July 30, 1902, for cardiac incompetence. She had been in the hospital many times before, because of sequelæ of acute rheumatism 14 years previously. She died of failing compensation, Nov. 12, 1912.

P.M. Cor bovinum, tricuspid regurgitation, mitral stenosis, patent foramen ovale; bilateral hydrothorax, ascites; passive congestion of organs; accessory spleen.

Micro. Exam. There is diffuse increase of the interstitial tissue with great congestion of the pulp. The Malpighian bodies are few, small, and contain only lymphoid cells. The walls of the central vessels are increased in thickness and show hyaline change.

Ref. : E. 5353c. R.V.H. 159.12.

PRESENTED by Dr. Gruner.

43.222⁵ Passive Congestion of Spleen in Cardiac Disease (Late Stage).

An organ, slightly reduced in size, having a finely granular surface with a few shaggy adhesions, of firm consistency. The natural shape is preserved (anatomical depression due to stomach). The cut surface is of a dark maroon colour, and shows increased fibrous tissue. The Malpighian bodies are conspicuous against the red background.

E. A., female, aged 42. From a case of chronic heart disease of long standing.

Ref. : R.V.H. 80.02. E. No. 816. See also 11.39⁸.

PRESENTED by Drs. Adami and Hamilton.

.26 Infarction.**43.26¹ Multiple Infarcts of the Spleen with Miliary Abscesses (?)**

The spleen of an infant, measuring $6.5 \times 3 \times 1.5$ cm., dark red in colour, soft and spongy over the greater part of its surface, but hard and firm in a few localized areas. These hard parts are the infarcted areas; dark reddish-brown irregular-shaped patches are scattered over all sides of the organ and sharply defined from the surrounding tissue. The largest of these measures about 1 cm. in diameter; on section it is seen to consist of a firm, dark-red outer area, and a soft, almost necrotic, bright-red central portion. The organ is studded all over with tiny yellow nodules closely resembling miliary abscesses.

Ref. : St. Bart's. 1907. Entry No. 3816.

PRESENTED by Dr. C. F. Martin.

43.26² Hæmorrhagic Infarction of Spleen.

A portion of a spleen cut open to show a small infarct of dark colour. The external surface is purplish in hue, but neither raised nor depressed. The cut surface shows the lesion to be sharply demarcated from the pale pulp. A few foci of deep congestion, clearly marked off against the pale pulp, are shown in the other portions. The organ measured $12.5 \times 5.5 \times 2.5$ cm. and weighed 200 grm.

A. B., male, aged 62, was admitted to R.V.H. on Nov. 22, 1911, because of rupture of the urethra five days before. The genitalia were gangrenous; the local condition was very bad.

P.M. Stricture of urethra following gonorrhœa; rupture of urethra; extravasation; cellulitis; abscess of right lung; hæmorrhagic infarcts of kidneys; thrombosis of pelvic veins.

Micro. Exam. The Malpighian bodies are few in number, and small in size. The trabecular tissue is inconspicuous. The venous sinuses are engorged.

Ref. : E. 4770b. R.V.H. 165.11.

PRESENTED by Dr. Gruner.

43.26³ Red Infarct of Spleen following Malignant Endocarditis.

A piece of a spleen cut through to show a red infarct at the edge. This has an ill-defined sinuous outline. The surface of the infarct is level with that of the spleen and shows hardly any change in colour. A pale border can be detected with a very narrow zone of congestion next to it.

Mrs. S. T., aged 24. Two weeks before death suddenly developed weakness, followed by right-sided paralysis and aphasia. High septic temperature. Was pregnant seven months; labour was induced, followed in a few hours by death.

P.M. Malignant endocarditis; generalized septicæmia; softening of area of Broca; infarcts of spleen and kidney; acute endometritis.

Ref. : M.G.H., A. 11.143. E. 4935. See also Specimen No. 13.33.

PRESENTED by Dr. Rhea.

43.26⁴ Infarct in Spleen of Passive Congestion.

A small spleen, whose capsule shows a few adherent tags of adhesions. The organ is laid open to show a small wedge-shaped infarct with a white centre and a broad reddened periphery. There is an increase in the fine reticular tissue throughout the pulp.

PRESENTED by Dr. Adami.

43.26⁵ Multiple Infarcts in a Cardiac Spleen.

A small spleen, measuring $10 \times 6 \times 3$ cm., of very pointed shape. The cut surface shows some large infarcts of grey colour, with bright-red sinuous borders. The spleen pulp is bright red in colour. The capsule is very markedly wrinkled but otherwise natural.

Old Museum specimen.

43.26⁶ Multiple Infarction of Spleen in Acute Endocarditis.

A moderately enlarged organ with tense capsule. A series of wedge-shaped white infarcts, of very irregular outline, are scattered

through the middle third of the organ, and their central parts are softened. The capsule of the spleen over the infarcted areas is opaque but not thickened, although there are tags of lymph adherent to its surface in other parts.

Daniel McK., aged 29. Tonsillitis at 29, but no rheumatic history. Illness commenced nine months previously with pneumonic symptoms and later cerebral thrombosis, or embolism.

P.M. Recurrent aortic endocarditis with vegetations on and perforation of left anterior cusp. Acute sero-fibrinous pericarditis. Acute sero-purulent peritonitis with thrombosis of superior mesenteric artery and gangrene (infarction) of intestines. There are white infarcts of the liver and kidneys and infarction of brain.

The spleen weighed 225 gm., and measured $13 \times 10 \times 3$ cm.

Ref. : R.V.H. 49.02.

PRESENTED by Dr. Adami.

43.267 Multiple Infarcts and Passive Congestion of Spleen following Cardiac Thrombosis.

A spleen, weighing 155 gm. and roughly of normal size. There are some recent plastic and some older organized adhesions with fibroid patches of thickening of the capsule; some more recent fine granulations, as from recurrent perisplenitis, also occur. At the inner border of the upper end is a white area corresponding to an infarct, 2 cm. wide, which has been cut across. Several other infarcts show through the capsule. A constriction occurs at the lower end, cutting off, as it were, a sessile portion of the organ, 2×2 cm., but this is probably congenital in origin, as there is no increase of fibrous tissue to account for it pathologically. Two recent and somewhat redder infarcts occur in the middle third of the organ. The cut surface shows hæmorrhagic zones round the infarcts, and a very large infarct, partly softened in the middle, occupying nearly one-third of the organ. The Malpighian bodies are very distinct and the pulp very congested and dark in colour.

William H., aged 27, janitor, admitted to the R.V.H. Sept. 19, 1909. Had been ill for three weeks before admission, and had had pains in the legs for two months. Died on Dec. 11, 1909.

P.M. Generalized arterio-sclerosis, hypertrophy and dilatation of the heart, parietal thrombi of both ventricles, multiple infarcts of the lung and one of the heart. The pelvic veins were thrombosed,

and there was passive congestion of all organs with anasarca. Infarcts of spleen.

Micro. Exam. There is thickening of the coats of the smaller vessels. The Malpighian bodies are very distinct and the pulp congested.

Ref. : R.V.H. 138.09. E. 4035a.

PRESENTED by Dr. Adami.

43.26⁸ Multiple Infarcts of Spleen following Acute Vegetative Mitral Endocarditis.

The spleen shows several irregular areas of light yellowish colour on the surface, wedge-shaped on section. Depressions and puckering are present at the upper pole. There is also a large deep depression along the posterior border of the upper pole. On the cut surface a number of yellow wedge-shaped areas are seen along the border of the organ.

B. R., female, aged 35, was admitted to the R.V.H. August 16, 1909, having been ill five weeks. She was found to have chronic endocarditis with mitral stenosis.

P.M. Malignant endocarditis, acute vegetative mitral endocarditis with septic myocarditis, bilateral hydrothorax, multiple necroses of liver. Infarcts of spleen; weight, 150 gm.; size, 13×9×3.5 cm.

Ref. R.V.H. 110.09. E. 3853b.

PRESENTED by Dr. Gruner.

43.26⁹ Multiple White Infarcts in Enlarged (Febrile) Spleen of Case of Acute Vegetative Endocarditis.

A slab, 17×8.5 cm., from a greatly enlarged spleen showing two large infarcts. The surface is smooth, the capsule tense, and there is a depression at the upper edge of the lower infarct. The surfaces of both are slightly roughened with lymph and partly pitted. The cut surface shows retraction of the splenic pulp, almost complete replacement of splenic tissue by infarctions. The edges are very irregular and finely scalloped. The central parts are dark brown in colour and a little hollowed. The pulp itself is very dark-

coloured, and the Malpighian bodies are obscured. Another piece of spleen in the same jar shows an old white infarct of wedge-shape, with a smooth surface, uniform yellow colour on section, scalloped edge, and narrow translucent limiting line.

Mrs. McN., aged 43, was admitted to the M.G.H. May 29, 1908, suffering from cough, weakness, and anæmia. History of exposure to cold in February 1908; since then had had drenching night-sweats and had lost 40 pounds in weight. Examination showed enlargement of spleen, liver, and heart, and marked secondary anæmia. The patient gradually failed and had four convulsions during the last ten days of life. Death occurred in coma following delirium.

P.M. The spleen weighed 1,005 gm. and projected 8 cm. below the left costal margin. It was adherent to the diaphragm. Other findings were acute vegetative endocarditis (mitral and aortic), fatty liver, acute and chronic nephritis.

Ref. : M.G.H., A. 08.167. E. 3532.

PRESENTED by Dr. Wolbach.

43.26¹⁰ Multiple White Infarcts of Spleen.

The specimen consists of half a large spleen, measuring $16.5 \times 10.5 \times 3$ cm., whose cut surface reveals at the lower third a large triangular infarct of white colour (5.5×3.2 cm.), raised, and having slightly serrated margins. It is separated from the splenic tissue by a narrow translucent line. A second smaller infarct occurs at the junction of the upper and middle thirds. A few white spots seen in the immediate vicinity of the main white mass are portions of the same infarct, which have been cut through irregularly owing to the shape of its lower end.

The remainder of the cut surface is pale and shows large Malpighian follicles. The capsule presents no abnormality. The surface of the infarct is hardly visible beneath the capsule.

Miss E. R., aged 83. Admitted with impacted fracture of left femur. Died from exhaustion.

P.M. Chronic myocarditis. Purulent bronchitis. Calcareous lymph-nodes. Enteroptosis and dilatation of stomach. Chronic nephritis. Arterio-sclerosis and calcification. Decubitus ulcers. Infarcts of spleen.

Micro. Exam. The spleen substance away from the infarct shows loss of ordinary structure, being almost entirely lymphoid.

The cells amongst the trabeculæ are very numerous, uniformly distributed, and all of a size, as if a pseudo-leukæmic condition was present.

Ref. : M.G.H., A. 10.152; S. 10.1064. E. No. 4523.

PRESENTED by Dr. Rhea.

43.26¹¹ Spleen. Infarct.

A slab from a markedly enlarged spleen, showing an old infarct of large size, whose surface is shaggy and whose cut surface is pale, mottled, and shows a scalloped edge, marked off by hyaline fibrous tissue.

PRESENTED by Dr. Abbott, 1902.

43.26¹² Spleen showing White Infarct with Depressed Scars and Patches of Hyaloseriosis.

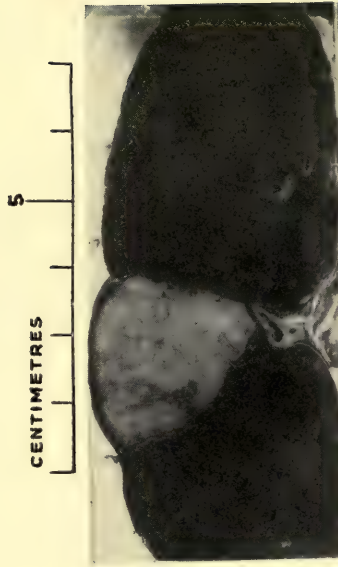
A small spleen whose surface shows a triangular area of yellowish discolouration with three small outlying irregular plaques of opaque substance. Across the upper end is a transverse deep furrow. Other plaques occur above this, as well as a small infarct. On the pole opposite to the first-named wedge-shaped area is a second deep pucker. The cut surface shows thickenings of the capsule, corresponding to the plaques, and a yellow discolouration around the edges of the second furrow. The wedge-shaped area has the same shape on section, and is of dark colour in the centre, but its edges are white and there is a very fine red line delimiting it. The Malpighian bodies are enlarged. The pulp is dark in colour, and there is no increase in the fibrous trabeculæ.

Ref. : E. 3599.

43.26²⁰ Infarct of Spleen following Acute Mitral Endocarditis.

A slice of spleen showing a large wedge-shaped infarct of pale pink colour occupying the centre of its length. At each border the

PLATE VIII



43.26²⁰ OLD INFARCT IN CARDIAC SPLEEN

Dr. C. F. Martin



capsule is depressed. The outline, within the spleen substance, is regular and sharply mapped out by a narrow ochre-coloured line.

From a girl who died of infective mitral endocarditis complicating otitis media.

Ref. : St. Bart's. E. 2246.

PRESENTED by Dr. Martin.

43.26²¹ Old Infarct of Spleen following Acute Vegetative Endocarditis.

A small spleen whose posterior border is occupied at the junction of middle and lower thirds by a large white infarct 4.5×3.5 cm., which is triangular in shape externally. It is very clearly marked off by deep sulci all round it. The spleen is smooth everywhere except over the infarcted area. A depressed puckered area, due to another infarct, occurs 3 cm. above the first.

The organ weighed 230 gm., and measured $13 \times 6.5 \times 3.5$ cm. It was flabby.

C. B., female, aged 45, was admitted to hospital for heart failure. Attacks of failing compensation had occurred repeatedly during the past five years. The infarction of the lung occurred on the day of death.

P.M. Acute vegetative endocarditis (mitral and aortic) and buttonhole stenosis of mitral valve. Multiple infarcts of lungs, spleen, kidneys. Extreme congestion of lungs. Septic thrombosis in right auricular appendix. Eccentric hypertrophy of the heart. *B. coli communis* was recovered from the heart, thrombus, and splenic juice.

Ref. : E. 4787. R.V.H. 164.11.

PRESENTED by Dr. Gruner.

43.26²² Old Infarction of Spleen in Malignant Endocarditis.

A greatly enlarged spleen, measuring $14 \times 9 \times 5$ cm. The pulp is soft and bulges outward. At the upper pole is a large quadrangular infarct of white colour, measuring 4×2 cm. At the lower pole and running up to the hilum is another enormous white infarct 9 cm.

long, involving the portion of the spleen comprising the lower two notches. It has no characteristic shape. The surface is roughened over each infarct.

Louisa L., aged 34. History of miscarriage.

P.M. Septic endometritis. Acute vegetative endocarditis of mitral valve (staphylococcus and streptococcus infection). Septic infarct of spleen with necrosis and rupture of organ. Acute localized fibrino-purulent peritonitis of upper abdomen.

Ref. : R.V.H. 38.03.

PRESENTED by Dr. Adami.

43.26²³ White Infarct of Spleen.

A spleen measuring $14 \times 5 \times 3$ cm. The surface is pale in colour, smooth, save over the infarction, where there is a rough depression 2 cm. wide and having tags of lymph adherent to it. The infarct occupies the whole thickness of the organ, is chalky-white in colour, has a smooth granular surface, and is almost homogeneous in structure. There is a very thin grey translucent limiting line. The infarct is an old one.

The rest of the splenic tissue is normal in appearance.

F. G., male, aged 46. Pain in leg set in eight weeks before admission. Amputation of thigh. Blood-culture showed streptococcic septicæmia.

P.M. Septicæmia following acute osteomyelitis of right leg; septic infarct of lung, kidney, and spleen; pyelonephritis; diphtheritic ulceration of cæcum and ascending colon.

Ref. : R.V.H. 48.08. E. 3374.

PRESENTED by Dr. Adami.

43.26²⁴ Old Infarct of Spleen. Passive Congestion of Cardiac Origin. Miliary Tubercles.

A much enlarged spleen, measuring $17 \times 9 \times 5$ cm., showing very deep irregular puckering across the middle line, due to old infarction. The surface is everywhere smooth and tense, except near the tip, which is roughened by recent lymph. The cut surface shows a large

ochre-coloured homogeneous patch, firm in consistence, of irregular outline, mapped out with a fine translucent line, and separated off from the spleen pulp by fibrous bands. The large vessels below show blood-clot in their lumen, and some minute white nodules enclosed in a bright-red zone occur, which are tubercles. There was tuberculosis of the liver. The spleen weighs 500 grm.

E. M., male, aged 52. The condition followed recurrent heart disease affecting the aortic cusps. Tuberculosis set in one and a half years before death.

Micro. Exam. Here and there are some small miliary tubercles whose centres are necrotic. One large one, occupying nearly the whole of a low-power field, is visible in the section. It shows centrally a hyaline mass with radiating clefts; at the periphery a narrow zone of infiltration enclosed in an outer zone of pale-staining hyaline matter. The zone of reactive infiltration round the whole is narrow. The trabeculæ are large, but the capsule is not thickened.

Ref. : R.V.H. 70.07. E. 3132a.

See also Specimen No. 37.361.

PRESENTED by Dr. Klotz.

43.26²⁵ Spleen. White Infarcts in Typhoid Spleen.

A portion of a small spleen, cut open to show a relatively white infarct (3.5 cm. in diameter) of ovoid shape. Its edges are depressed and its cut surface shows a regular contour. It is of pale fawn colour, and there is a semi-translucent hyaline border separating it from the splenic substance. The spleen appears otherwise normal. (Weight 345 grm.)

R. de C., male, aged 24, was admitted to the M.G.H. on Dec. 20, 1912, with signs of typhoid fever. Widal positive. White cells, 7,900. Fluid was found in the chest.

P.M. Pyopneumothorax; abscess of lung; bronchopneumonia; ulcerative enteritis; chronic peritonitis. The spleen was bound down by many fibrous adhesions to the stomach, transverse colon, and sigmoid. There were several infarcts, some undergoing softening. They were more numerous on the under surface near the hilum.

Note how small the spleen is for a 'febrile' type.

Ref. : E. 5570. M.G.H., A. 13.12.

PRESENTED by Drs. Finley and Burgess.

43.26²⁶ Infarction of Spleen of Long Standing.

Half of a slightly enlarged spleen. A large, wedge-shaped white infarct, raised above the surface and demarcated from the surrounding tissue by a deep ridge, is situated at the upper pole (lower in jar). Its cut surface is of cheesy consistency and shows a deep yellow narrow delimiting line (remains of hæmorrhagic zone). At the junction of the lower and middle thirds of the organ is a retracted linear scar with cheesy matter in its centre, which represents the remains of a second old infarct. The surfaces are a little shaggy with lymph.

Ref. : E. No. 936.

43.26²⁷ Infarct in Cardiac Spleen.

A small organ of deep-red colour. The cut surface shows a marked increase of fibrous tissue, and the outer surface is finely granular. Towards the upper pole there is a depressed yellowish wedge-shaped area, of cheesy consistency, sharply delimited from the rest of the spleen (old infarct). The pale tract in the centre is artefact.

J. McE., male, aged 47. Recurrent mitral endocarditis in old mitral stenosis. Infarcts of spleen, lung, kidney, and colon (ulcers from infarction). Early cirrhosis of liver.

Ref. : M.G.H. 190.03. E. No. 976.

PRESENTED by Dr. Gillies.

43.26²⁸ Spleen showing White Infarcts (Arterio-sclerotic).

Half a spleen, measuring 9 × 6 cm., showing three large infarcts, one at each pole and one stretching across the middle third. They are sharply marked off by deeply congested splenic tissue which is rather fibrous. The surface of the spleen is unaltered and neither depressed nor elevated.

Jane E., aged 58. Died on admission. No clinical notes.

P.M. Pyonephrosis; acute cystitis; arterio-sclerotic atrophy of kidney; obsolete and active tuberculosis of lungs and intestine and glands; sclerosis and tortuosity of the splenic arteries with

a mural thrombus partially occluding the lumen. The spleen weighed 100 gm.

Micro. Exam. Fibrosis of the spleen with infarct of some days' duration, with, however, little organization.

Ref.: R.V.H. 9.10. E. 4152a.

PRESENTED by Dr. Adami.

43.26²⁹ Multiple Infarcts of Spleen.

A moderately large but bulky spleen, showing tags of lymph upon its surface and several infarcts. The lower pole is occupied by one large infarct with clean-cut borders marked off by a bright ochre-red line, and a hyaline line within that. The centre of this infarct is markedly softened. String adhesions are attached all round its border. There is a sulcus demarcating it superficially. At the upper pole is a small wedge-shaped infarct definitely raised about the surface, having an irregular purple line enclosing it. On the cut surface there is a similar appearance to the preceding, but the softening is not as intense in the infarct at the lower pole. A still smaller infarct occurs half-way along the spleen. The pulp-tissue is pale. There is some dark mottling in the central portion.

From a girl, aged 13, who had chronic heart disease following attacks of rheumatism at the ages of 5 and 7.

P.M. Chronic myocarditis; chronic interstitial and acute parenchymatous nephritis; chronic passive congestion of liver; infarction of spleen; acute and chronic bronchitis; acute inflammation of bronchial lymph-nodes.

Micro. Exam. The section for the most part shows necrotic tissue in which scarcely any cellular element can be made out and in which are collections of fibrin. In other places the splenic tissue has been preserved, but the sinuses are greatly dilated and empty, except for occasional red blood-cells.

Ref.: E. 4627. R.V.H., A. 09.104.

PRESENTED by Dr. Gruner.

.3 INFLAMMATION.**.324 Hæmorrhagic Inflammation.****43.324¹ Hæmorrhagic Splenitis and Accessory Spleen.**

Part of a spleen, measuring $15 \times 8 \times 4$ cm. and weighing 215 gm., cut open to show numerous rounded areas of extremely dark colour, varying in diameter from 2–12 mm. Their contour is regular. The remainder of the organ is congested and shows innumerable small Malpighian bodies.

The exterior shows nothing worthy of special note, except that there is an accessory spleen in the attached gastro-splenic omentum.

Mrs. A. McE., aged 41. Admitted to the R.V.H. Nov. 6, 1910, for vomiting and jaundice. An operation for gall-stones was performed fifteen days before death. The adnexa of this operation are shown in Specimen No. 38.65.

P.M. Cholelithiasis; chronic cholecystitis; obliteration of cystic duct; chronic peritonitis; fat-necrosis of pancreas; chole-dochostomy; chronic pancreatitis.

Micro. Exam. There is slight thickening of the capsule. The trabeculæ are hyaline in places. The Malpighian bodies are increased in number, but are small and ill-defined in outline. The pulp is undergoing necrosis here and there, and is poor in cells; many of the splenic channels are dilated, and show desquamating and endothelial cells in their lumen. There is no increase in the elastic tissue. Foci of recent inflammatory exudate (fibrinous) occur.

Ref.: E. 4498b. R.V.H. 162.10.

PRESENTED by Drs. Gruner and Garrow.

43.324² Spleen. Acute Hæmorrhagic Splenitis in Lobar Pneumonia.

Two slabs from an enlarged spleen, measuring 16×7 cm. The capsule is smooth, dark purple in colour, and quite tense. The cut surface is deep red, mottled with almost black markings of arborescent pattern.

E. P., male, aged 45. Illness began on March 16, 1908, with pains in the side and vomiting; also cough with expectoration, which was profuse and of a rusty colour and sometimes contained blood. Patient died at 1.30 p.m. March 23, 1908.

P.M. Lobar pneumonia; acute pericarditis; acute and chronic nephritis; acute bronchitis; chronic and healed mediastinal tuberculosis.

Spleen was enormously enlarged, weighing 720 gm. The capsule is tense and black. On section the cut surface presents a very curious red and black appearance. The upper portion of the surface is bright red, but scattered through the red parts are numerous black areas with sharp irregular outline. The organ is very friable and much pulp comes away on scraping. The trabeculæ and Malpighian bodies are invisible.

Micro. Exam. The capsule is moderately thickened. The trabeculæ are a little thickened but not conspicuous. The pulp is almost entirely occupied by blood which tensely fills all the sinuses. There are few pulp-cells to be made out. The Malpighian bodies are reduced to traces and contain no germ cells.

Ref. : E. 3227. M.G.H., A. 08.67.

PRESENTED by Dr. Duval.

43.324³ Hæmorrhagic Splenitis.

A small spleen, measuring $9.5 \times 6 \times 3$ cm. and weighing 90 gm. It is rather depressed by a deep notch. The capsule is grey from thickening. The cut surface is lightly variegated by alternating areas of pale yellow and dark red, of about equal size, and almost 4 mm. in diameter. The Malpighian bodies are somewhat large but not easily seen.

N. S., male, aged 61, was admitted to the R.V.H. April 15, 1913, suffering from bladder symptoms which proved to be due to an enormous papilloma of bladder (see Specimen 53.752). Death occurred six days after operation.

P.M. Papilloma of bladder; petechial hæmorrhages in kidney pelvis; enlarged lumbar glands; adrenal hyperplasia; fatty heart.

Micro. Exam. The main change is one of dilatation of the blood-channels with outflowing of free red blood corpuscles into the pulp-tissue. Fibroblastic cells are very numerous. The central vessels of the Malpighian bodies have thick hyaline walls.

Ref. E. 5521. R.V.H. 41.13.

PRESENTED by Dr. Gruner.

.325 Purulent Inflammation (Abscess).**43.325¹ Spleen with Suppurating Infarcts in Typhoid Fever.**

Half of a moderately enlarged spleen measuring 15×9 cm. The cut surface shows three infarcts of wedge shape, one on the anterior and one on the posterior border, and one at the tip. The central infarct has a soft centre, leaving a small cavity with ragged edges, and roughened yellowish walls. The anterior infarct and that at the tip are also undergoing softening and form cavities with a similar appearance to that of the central infarct. The surrounding spleen substance is diffusely congested. The outer surface shows a diffuse irregular opacity with characteristic linear grooving (a patch of hyaloserousitis). Apart from this there is no evidence of perisplenitis.

Note. A slab from this specimen presents a small suppurative infarct irregularly cavitated, which is shown as a Petri dish specimen. Another slab is mounted in a square jar, and numbered 43.351⁵.

Micro. Exam. Section I shows a large area of necrosis with a few scattered collections of small round cells; the remains of blood-vessels are in their vicinity.

Section II shows intense outpouring of red blood corpuscles, the edges of the region being well defined. A couple of Malpighian bodies are seen.

For history see under 43.351⁵ and 42.351².

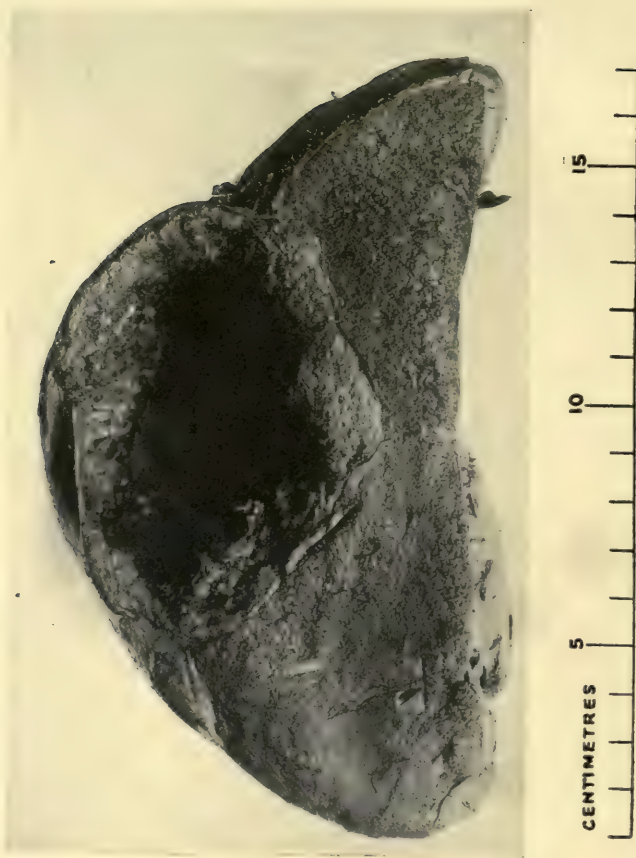Ref. : M.G.H., A. 207.09. E. 4064b.

PRESENTED by Dr. Wolbach.

43.325² Broken-down Suppurative Infarct and Hyaloserousitis in Spleen of late Passive Congestion.

A small spleen, $7\frac{1}{2} \times 4\frac{1}{2}$ cm. in cross section, showing semi-translucent, opaque, irregular surface, smooth in some areas, with numerous tags of lymph attached here and there in others. The cut section shows a band of yellowish softened material crossing the middle line of the spleen, having clearly defined hyaline scalloped edges. The softened material is shaggy in places, and several irregular cavities appear in it. The cut edge of the surface on the one side is greatly thickened by the semi-translucent cartilaginous-

PLATE IX



43.325^s SEPTIC INFARCT, ABSCESS IN SPLEEN,
OF MALIGNANT ENDOCARDITIS

Note large size and diffluent appearance of organ, and
excavated wedge-shaped area

Dr. Fraser Gurd

looking material in which a little lamination can be detected. There is a narrow bright-yellow band demarcating the original capsule along the whole of this surface of the spleen. The pulp itself is pale, with red blotchings, in which Malpighian bodies are only faintly discernible.

G. I. R., male, aged 69. Illness began with acute lobar pneumonia on the right side four weeks before death. One week before death a quart of foul pus was removed. There was recurrent valvular heart disease (mitral endocarditis).

P.M. Empyema; recurrent valvular heart disease; acute mitral endocarditis on mitral stenosis; chronic interstitial nephritis and multiple infarcts of the kidneys and spleen. The splenic artery was smaller than usual.

Ref.: R.V.H. 3.09. E. 3485.

PRESENTED by Dr. Klotz.

43.325³ Spleen showing Septic Infarct with Central Breaking Down in Malignant Endocarditis.

A slab of an enlarged spleen showing a large cystic swelling occupying the middle portion. Elsewhere the organ is somewhat softened and deep purple in colour. The round swelling is formed by an abscess, which contained about 180 c.c. of deep purple-coloured purulent fluid. The wall of the cavity is rough and consists of purplish granular friable material. The part approximating the splenic pulp proper is V-shaped in outline, and consists of bright yellowish, moderately firm tissue, measuring 0.5 cm. in width. The pulp is dark. The Malpighian bodies are not visible.

C. McC., male, aged 44, had been ill for eight months, and for two months had been laid up with irregular fever, cough, and dyspœna. Enlargement of the heart and a mitral systolic murmur were found. Three days after admission drowsiness came on, passing into coma, temperature rising to 104°-105°. Lumbar puncture, Widal and blood-culture were negative. Leucocytes numbered 11,450. Paralysis of the right eye muscles, and hæmorrhage into the fundus shortly preceded death.

P.M. Acute endocarditis (mitral and aortic); infarcts of kidney and spleen; acute suppurative appendicitis; chronic pleurisy; acute localized leptomeningitis. Polypus of jejunum (see Specimen No. 351.752).

Micro. Exam. Section I. Section in general is made up of two

parts—a normal-looking area of splenic tissue and a large necrotic area—which are separated by a broad, dense, fibrous-tissue band. In the normal area the Malpighian bodies are moderately numerous, distinct, and large. Several contain a few cells with a large amount of pink-staining protoplasm and vesicular nuclei (endothelial cells). The sinuses contain a moderate number of red blood-cells. There is an increased number of lymphoid and plasma cells and eosinophiles throughout the pulp, and in places an increase in the connective-tissue stroma. The necrotic area is largely made up of shadows of cells taking the red stain intensely and devoid of nuclei. Throughout these are numerous polymorphonuclear leucocytes. In places there are crystals, bright yellow in colour and needle-shaped in appearance. The broad band of fibrous tissue separating the necrotic from the healthy tissue is infiltrated with numbers of lymphoid and plasma cells and a few polymorphonuclear leucocytes. This tissue also contains large cells, many of them polynuclear with vesicular nuclei, phagocytic for the light-yellow (blood) pigment. Many large cells contain these light-yellow needle-shaped masses.

Section II. Similar to I. The vessels are more injected, especially those in the fibrous-tissue area and adjacent splenic sinuses. The necrotic zone contains in places strands of fibrin and collections of cocci occurring in chains. The reticulum and cells of the pulp are distinct as pale-red-staining shadows. Collections of crystals are seen throughout the infarcted area and the periphery.

Section III. The section is injected, especially in the neighbourhood of the fibrous-tissue area. It is similar to the other two. The polynuclear cells in the tissue surrounding the necrotic zone are very numerous and well formed; the cells are not very large, few contain *more than 6-8 nuclei*. The nuclei of several are intensely black and the protoplasm pink: contain bright-yellow needle-shaped crystals, as well as blood pigment.

Ref.: M.G.H., A. 236.07. E. 3221a.

PRESENTED by Drs. Molson and Gurd.

43.325⁴ Multiple Abscesses of Spleen.

Half of a spleen with the capsule adherent to the diaphragm, torn from the splenic substance. The surface so exposed is very rough, owing to a fine honeycombing with minute holes of various sizes.

The cut surface shows a number of rounded pale areas with rather ill-defined outlines. Their centres are irregularly softened (honeycombed). These are the abscesses of varying size, showing no relation to anatomical structures. The remainder of the splenic tissue is very pale. The Malpighian bodies are small.

M. H., female, aged 40. Admitted Sept. 20, 1909, complaining of dyspnoea, abdominal pain, and great weakness. Has been confined to bed with above symptoms one month previously. There was marked orthopnoea, abdominal rigidity, tenderness, and pain in the sides; oedema of feet. Systolic murmur transmitted to the axilla. Discharging ischio-rectal sinuses. Died Sept. 27, 1909.

P.M. Chronic myocarditis and endocarditis; hydrothorax fatty liver; acute peritonitis; salpingitis; perirectal abscesses; acute cystitis; multiple fistulae in ano.

Micro. Exam. Shows the splenic pulp very congested and in places breaking down. The Malpighian bodies are moderately numerous, and lymphoblastic pulp-cells are abundant, rather large, and pale.

Ref.: E. 4460. M.G.H., A. 09.171.

PRESENTED by Dr. Rhea.

.34 Specific Inflammations due to Cocci.**43.34¹ Acute Splenitis in Gangrenous Appendicitis.**

Half of a bulky spleen of moderate enlargement, with rounded edges. The outer surface is purple, slightly mottled, with pale spots here and there. The capsule is tense. The cut surface is characteristic ; it is mottled with dark-purple areas of irregular size and ill-defined outline, alternating with paler ones. Throughout can be seen innumerable minute deep-red spots of round shape with white centres. These are the greatly engorged Malpighian bodies. In some parts the splenic tissue is softening.

L. M., male, aged 24. Admitted to the R.V.H. on July 10, 1912, for jaundice and abdominal pain. He had been ill one month, the onset being sudden. A laparotomy was performed. Died August 12th.

P.M. Gangrenous appendicitis with pelvic abscess and secondary suppurative pylephlebitis. Acute toxic adenitis of aortic glands (42.31¹). Sternum, puriform marrow.

Micro. Exam. The Malpighian bodies are few, rather small ; the pulp-channels are very wide, and full of blood. The pulp-cords contain a moderate number of many varieties of cells, and the relics of necrotic cells.

Ref. : E. 5243. R.V.H. 113.12.

PRESENTED by Dr. Gruner.

.341 Lesions due to Micrococci.

None in this series.

.342 Lesions due to Staphylococci.

None in this series.

.343 Lesions due to Streptococci.

**43.343¹ Spleen in Septicæmia (Acute Splenitis).
Septic Infarct.**

A very large spleen, 15×11 cm. The capsule is tense, with recent plastic exudate and some small spots of fibroid peritonitis. The recent inflammation was most marked over an area of 8.8 cm. on the anterior inferior aspect, in the centre of which was a softened patch of spleen tissue which ruptured on removal and revealed thin gangrenous contents. When this area was cut open it was triangular in shape, the base 5 cm. across. The rest of the splenic tissue was dark, swollen, and very pulpy.

Mrs. T. S., aged 36, was admitted to R.V.H. the day before death suffering from puerperal septicæmia, which developed on the third day after labour. Delivery one month previously.

P.M. Septic endometritis; septic thrombosis of pelvic veins and inferior vena cava; streptococcal infection; infarcts of lung; acute aortic endocarditis; acute peritonitis; acute splenitis with septic infarcts; focal necrosis of liver.

Ref.: R.V.H. 39.09. E. 3579.

PRESENTED by Dr. Klotz.

43.343² Spleen in Acute Endocarditis.

A large spleen, measuring $21 \times 10.5 \times 5$ cm. and weighing 465 gm.; of pale colour. There are two slit-like notches, and the surface is rendered uneven by the presence of four old depressed infarcts and one deep scar. The surface is slightly granular and shows some

adhesions on the inner side. The cut surface is characterized by possessing the same colour as the outside and by being peppered by very conspicuous Malpighian bodies. The pulp-tissue is quite firm, but trabeculæ are not conspicuous. The infarcts have the characteristic wedge shape. The organ is almost pear-shaped.

J. F., aged 23, male. Admitted August 13th, died Oct. 25th. Illness of three months' duration with pains in joints, dizziness, and cough. The most important physical findings were enlarged heart, capillary pulse, and murmurs of mitral and aortic endocarditis. The blood-culture showed streptococci.

P.M. Recurrent endocarditis, mitral and aortic; chronic polyorrhomenitis; aneurysm of aortic valve; hypertrophied, dilated heart; œdema of lungs; recent pleurisy; enlarged spleen; aplastic bone-marrow; large mottled kidneys; miliary tuberculosis of lung.

The case was decidedly 'scorbutic'. The heart and kidneys presented a very instructive picture (see P.M. report). The spleen was not of the cardiac type. The blood-culture showed streptodiplococci.

Ref.: E. 5647. R.V.H. 125.13.

PRESENTED by Dr. Gruner.

.344 Lesions due to Pneumococci.**43.344¹ Acute Splenitis in Pneumonia.**

A very large spleen, measuring $18 \times 11 \times 7$ cm., and weighing 675 grm. The edges are rounded and the surface is smooth. There are no notches. The shape is quadrangular. The capsule is tense.

The cut surface shows little differentiation, the Malpighian bodies not being visible, and the trabeculae not being increased. There is mottling with small areas of congestion.

N. A., an Italian, male, aged 29, was admitted to the R.V.H. on Nov. 9, 1913, for lobar pneumonia of one week's duration. The clinical side of the case was entirely that of pneumonia. White cells, 17,400. The spleen was palpable.

P.M. Lobar pneumonia (R.); petechial hæmorrhages in pericardium; pleural effusion (R.) and recent fibrino-pleurisy (R. and L.); enlarged spleen; congested kidneys.

Micro. Exam. There is no change in the capsule and trabecular structures. Malpighian bodies are very sparse. The pulp is rich in fibre-cells, which leave the blood-channels readily visible in many places. The specific pulp-cells are diminished in number.

Ref.: E. 5670b. R.V.H. 131.13.

PRESENTED by Dr. Gruner.

.348 Lesions due to Meningococcus.**43.348¹ (Febrile) Spleen in Cerebrospinal Meningitis.**

A much enlarged spleen of firm consistence and rounded edges, measuring $17 \times 10.75 \times 5$ cm., and weighing 375 gm. The surface is smooth, grey in colour, and the capsule tense. On the cut surface the Malpighian bodies are visible but not enlarged; the pulp is abundant, dark red, and rather soft; the trabeculæ are not increased.

J. S., a Chinaman, aged 18. Admitted to R.V.H. Jan. 21, 1913, with characteristic symptoms and signs of cerebrospinal fever. He had been ill nine days. The organism was grown. Pasteur serum failed to cure. White-cell count, 12,800. Cerebrospinal fluid, 135 cells per c.mm.; lymphocytes, 88.4%; polymorphs, 10.8%; endothelials, 1.09%.

P.M. Suppurative cerebrospinal meningitis, choroiditis, and abscess in lumbar spine. Focal necrosis of liver; white bile. Ulcer of stomach.

Micro. Exam. The Malpighian bodies are diminished in size and number. Some necrosis in their centres. The pulp-tissue is preponderant; it is very congested. There is active desquamation of the endothelium of the vessels. Pulp-cells are moderately numerous. Small pigmentophages are abundantly present.

Ref.: E. 5413a. R.V.H. 12.13.

PRESENTED by Dr. Gruner.

.35 Specific Inflammation due to Bacilli.**.351 Typhoid.****43.351¹ Spleen in Typhoid Fever.**

A much enlarged spleen, $16 \times 8 \times 4.5$ cm., smooth, save for a few recent adhesions on the inner surface, and showing a small accessory spleen in the hilum. One constriction occurs which leads to the formation of a pedunculated nodule near the upper end. Notchings are indistinct. The cut surface is very dark and uniform in colour, and shows very conspicuous Malpighian bodies. When fresh the consistence was fairly firm; not diffuent. The spleen weighed 465 gm. The round discolouration on the surface is artefact.

F. F., male, aged 21, died from hæmorrhage on the 13th day of the disease. There were numerous typhoid ulcers in the small intestine, but only one ulcer in the colon, in the transverse part.

Ref.: R.V.H. 11.08. E. 3190b.

PRESENTED by Dr. McCrae.

43.351² Acute Splenitis in Typhoid Fever.

A moderately large and bulky spleen with rounded edges, and of slate-grey colour. A well-marked notch occurs near the lower pole in front, and a smaller one half-way along the posterior border. A cautery mark is seen. The outer surface is smooth, grey, rather opaque; the capsule is tense. The cut surface was homogeneous. Malpighian bodies cannot be seen.

A. D., male, aged 21, out of work four weeks. Onset with loss of appetite and general malaise; became delirious and died with very toxic symptoms and hæmorrhage.

P.M. Typhoid ulceration of small intestine, large intestine, appendix, colon, rectum; acute splenitis; pulmonary apoplexy; cloudy swelling of organs.

Ref.: R.V.H. 4.09. E. 3484.

PRESENTED by Dr. Adami.

43.351³ Enlargement of Spleen in Typhoid Fever.

An organ measuring $18 \times 11.5 \times 4$ cm., of normal contour, with prominent notches, dark slaty-blue in colour, with smooth tense capsule. The discoloured, wedge-shaped area is an artefact. The specimen shows the size to which the spleen may attain in typhoid fever.

W. B. M., male, aged 30. Death in the 6th week of typhoid. Physical examination showed splenic dullness in the mid-axillary line, meeting the costal margin at the point of the tenth rib. The edge of the organ was readily palpable two fingers' breadth below the costal margin on deep inspiration.

P.M. Secondary mixed infection following upon typhoid. Acute suppurative and hæmorrhagic hemiglossitis. Suppurative follicular tonsillitis with pseudo-membrane. Acute lobar pneumonia. Healing typhoid ulcers of ileum and colon.

Ref. : R.V.H. 83.95. E. No. 652.

Report by Dr. Nichol's, *Montreal Med. Journ.*, 1896, p. 104.

43.351⁴ Enlargement of the Spleen in Typhoid with Septic Infarct.

A spleen of moderately large size, measuring 15×11.5 cm. The surface is slightly wrinkled and dotted by numerous minute white spots. At the upper end on the outer surface is a small, yellowish, slightly depressed area with sinuous markings—the surface of an infarct—in whose centre is a ragged cavity due to softening. Another typical, non-softened, white infarct is seen on the inner side. There are no notches. The cut surface is diffuent and bulges beyond the tense capsule.

No history.

43.351⁵ Abscess of Spleen in Typhoid Fever.

A slab of a deeply congested febrile spleen, showing an irregular cavity at one end. The edges are darker in colour than the remainder of the organ. The lining of the cavity is irregular. [A duplicate

slab is mounted as a Petri dish specimen, and a second in a square jar (43.325¹.)]

C. A., male, aged 17. Typhoid fever set in Nov. 22, 1909. Died Dec. 6th from toxæmia, on 15th day of disease. Spleen palpable.

P.M. Typhoidal ulceration and swollen solitary follicles of intestines; enlarged mesenteric lymph-nodes; acute splenitis with septic infarcts in spleen; cloudy swelling of liver and heart muscle.

The spleen weighed 350 gm., much enlarged and deep red in colour. At the upper pole on the antero-lateral surface was a greyish irregular area which on section proved to be an irregular, somewhat wedge-shaped infarct with the base at the capsule $2 \times 2.5 \times 1$ cm. The cut surface of the spleen is a deep-red colour, almost black; pulp bulges out, trabeculæ not seen, surface moist, very friable, a large amount of pulp coming away on scraping.

Micro. Exam. Section I shows a large area of necrosis with a few scattered collections of small round cells; the remains of blood-vessels are in their vicinity.

Section II shows intense outpouring of red blood corpuscles, the edges of the region being well defined. A couple of Malpighian bodies are seen.

See also Specimens Nos. 42.351² and 351.351.

Ref.: M.G.H. 207.09. E. 4064.

PRESENTED by Dr. Baird.

43.351⁶ Hæmorrhagic Splenitis in Typhoid Fever.

A much enlarged spleen, weighing 625 gm. and measuring $18 \times 7 \times 5$ cm. The edges are rounded and smooth. There are no adhesions; it is dark red in colour. The capsule is slightly wrinkled. The cut surface shows no differentiation of structure, the Malpighian bodies being invisible, and the trabeculæ are conspicuous; it is very dark red, the surface is mottled with hæmorrhagic areas. (One portion of the organ is cut away to allow the cut surface to be visible, without impairing the impression of the size of the viscus.) The organ was flabby and the pulp diffuent when fresh.

C. J., aged 42, admitted Nov. 21, 1911, for weakness, fever, headache, and general malaise. The illness began three weeks before with weakness and abdominal pain. The cerebral symptoms increased. White cells 3,200. Death occurred three days later, Nov. 24, 1911, in the fourth week of the disease.

P.M. Typhoid ulceration; hypostatic pneumonia; hæmorrhagic splenitis.

Micro. Exam. The capsule is thickened; the trabeculae are conspicuous. The Malpighian bodies are small and scanty and the pulp shows congestion. Germ-centre cells are numerous. The pulp sinuses are small, and are filled with lymphocytes and red blood-cells with occasional eosinophiles. There is endothelial hyperplasia around the Malpighian bodies.

Ref. : R.V.H. 163.11. E. 4767.

PRESENTED by Dr. Gruner.

.356 Lesions due to Anaerobes.**43.356¹ Spleen in Infection with *B. Aerogenes Capsulatus*, Congestion, and Miliary Tuberculosis.**

Half of a moderately enlarged spleen, showing a few flattened papules 2-3 mm. in diameter scattered irregularly over its surface. The capsule is a little roughened in one or two places, but is mostly normal and tense. The cut surface shows numerous pittings as if worm-eaten or from action of gas blebs (due to *B. aerogenes capsulatus*), and presents closely packed, circular, pale areas throughout its substance. Some of these come to the surface as the nodules already described.

Female, aged 20, dying of subacute miliary tuberculosis.

P.M. Chronic pulmonary tuberculosis; tuberculous ulcers in intestine; caseous mesenteric and lumbar glands. The spleen was congested and studded with yellowish cheesy masses the size of peas. The capsule showed adhesions.

Micro. Exam. Large areas of necrosis are noticed. They have ill-defined edges. The splenic tissue is breaking down everywhere without losing the differentiation of its cellular structure. The bacilli are found scattered through it.

Ref.: A.M.M. 2026. E. 1902.

PRESENTED by the Army Medical Museum.

.359 Specific Inflammation due to B. Pestis.**43.359¹ Splenic Tissue containing B. Pestis.**

Small portions of spleen for microscopic investigation.

Micro. Exam. The organ is intensely congested and shows a marked tissue reaction. The blood sinuses are filled with immense numbers of short bacilli, in many of which the bipolar staining, so characteristic of *B. pestis*, can be seen.

PRESENTED by Dr. J. M. Bell, Hong-Kong, through Dr. C. F. Martin.

.36 Specific Inflammations due to Acid-fast Bacilli.**.361 Lesions due to B. Tuberculosis.***Human Tuberculosis.***43.361¹ Miliary Tuberculosis of Spleen. (Petri-dish Specimen.)**

A slice of spleen, showing closely packed innumerable whitish foci of rounded shape. They have the appearance of enlarged Malpighian bodies. The organ is small.

Mrs. J. M., aged 40. Admitted to M.G.H. April 20, 1907, with hæmoptysis from pulmonary tuberculosis of nine months' duration. Ten days later hectic temperature. About 100 c.c. of blood were coughed up every night at about 9 p.m. Death occurred May 9th from such a hæmorrhage.

P.M. Chronic pulmonary tuberculosis with cavitation; caseating and calcareous bronchial, mesenteric, and retroperitoneal glands; recent pelvic tuberculous peritonitis.

Micro. Exam. Shows enlargement of Malpighian follicles. The pulp-tissue stains poorly.

Note. No tubercles in this section.

Ref. : M.G.H., A. 07.85. E. 4464.

PRESENTED by Dr. Rhea.

43.361² Miliary Tuberculosis of Spleen.

An enlarged, long, thin spleen, measuring $17 \times 9 \times 3$ cm. The surface is covered with shaggy adhesions, and scattered small nodules (tubercles) occur just beneath the peritoneum. The cut surface shows many miliary tubercles of recent character. The pulp is soft and diffuent.

From a married woman, aged 21. Admitted to the R.V.H. in July 1908, suffering from general symptoms existing three weeks. The first symptom noted was that of synovitis of right knee. On July 14th very severe headache came on, pain down the spine, and a chill occurred. She had lived in England till three months before her illness. Death occurred from cerebral involvement. The leucocytes numbered 7,960.

P.M. Acute miliary tuberculosis, involving the lungs, heart, spleen, kidneys, and knee-joint, meninges, pleuræ, peritoneum, and glands.

Micro. Exam. There are irregularly shaped tubercles in process of caseation dotted through the spleen substance, and hæmorrhagic areas present through the pulp.

Ref. : E. 3320. R.V.H., H. 83.08.

PRESENTED by Dr. Klotz.

43.361³ Miliary Tuberculosis of Spleen. (Petri-dish Specimen.)

A slab of spleen dotted with millet-grain-sized white nodules of irregularly rounded shape. Some of them are quite punctate. There is no surrounding zone of congestion.

M. W., female, aged 17. Case of generalized tuberculosis affecting the meninges, lungs, liver, spleen, kidneys, peritoneum, diaphragm, and intestine. There was a caseating tuberculosis of the peribronchial glands, which showed the oldest lesion. The miliary spread of the disease was recent. Symptoms were mainly meningeal.

Ref.: E. 3140. R.V.H. 84.07.

PRESENTED by Dr. Klotz.

43.361⁴ Miliary Tuberculosis of Spleen.

A slightly enlarged spleen, measuring $14 \times 8.5 \times 3$ cm. The edges are rounded, and the capsule, though slightly thickened, is smooth. The cut surface is pale and studded with minute white nodules. The trabeculæ, though perceptible, are not unduly conspicuous.

M. L., male, aged 33, was admitted to the R.V.H. July 13, 1910, after only a fortnight's illness. He had had an ischio-rectal abscess four years ago. The signs pointed to a chronic pulmonary tuberculosis, with right pneumothorax. Died Sept. 14, 1910.

P.M. Generalized tuberculosis; old cavitation in both apices; tuberculosis of genital organs, kidneys, lungs, adrenals, ileum.

Micro. Exam. The capsule is slightly thickened; the section is dotted over with miliary tubercles containing giant cells; many of the tubercles show central caseation. There is no definite relation between them and the Malpighian bodies; the latter are irregular in size.

See also No. 42.361⁹.

Ref.: E. 4364. R.V.H. 115.10.

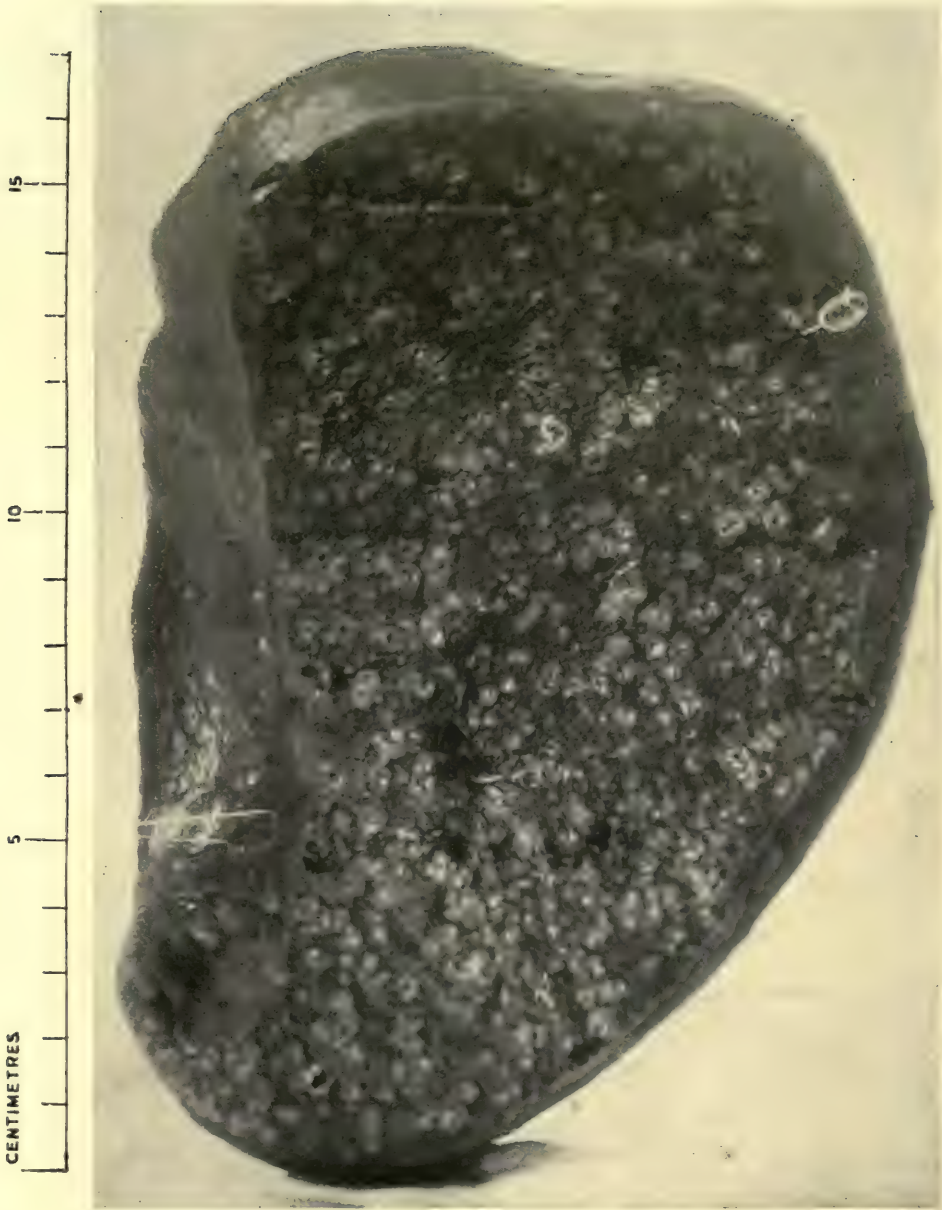PRESENTED by Dr. Gruner.

43.361⁵ Miliary Tuberculosis of Spleen.

A small spleen, the surface of which is covered with discrete raised yellowish nodules the size of a hemp-seed, which stand out very conspicuously against the dark spleen-tissue. The cut surface




PLATE X



43.361⁷ SUBACUTE MILIARY TUBERCULOSIS OF SPLEEN

Note large size of organ, and riddling with discrete white caseous nodules

Dr. Adami

shows that these nodules are very evenly distributed throughout the substance.

Ref. : E. 3257. Shadwell 7. Tuberculosis Series 47.

PRESENTED by Dr. Martin.

43.361⁶ Miliary Tuberculosis of Spleen. (Petri-dish Specimen.)

A small spleen cut in half. The surface is dotted with a small number of round white nodules of pin-head size ; they are bordered by a bright-red line, and are slightly raised above the surface. The cut surface shows the whole spleen riddled with similar nodules, but they are larger on the cut surface than on the outer surface ; they vary between 2 and 3 mm. in diameter, are whitish in colour, and bordered by a red line as in the case of the superficial ones.

M. W., female, aged 3. Had been ill for a month following whooping-cough. Died in coma six hours after admission.

P.M. Generalized miliary tuberculosis of spleen, intestines, genitalia, kidneys, lungs, pleuræ, peritoneum, heart, diaphragm, adrenals. Tuberculosis of mesenteric, peribronchial, retroperitoneal, periportal, gastric, and peritracheal glands.

The primary focus was in the peribronchial glands leading to a general blood infection.

Micro. Exam. There were many foci of miliary tuberculosis ; these had mostly a caseating centre with giant cells distributed about them.

Ref. : E. 3323. R.V.H. 3.07.

PRESENTED by Dr. Klotz.

43.361⁷ Subacute Miliary Tuberculosis of Spleen.

The specimen consists of an enlarged spleen, measuring $17 \times 7.5 \times 7.5$ cm., with a smooth tense surface showing no notching, dark in colour, with numerous white mottlings which are slightly raised and have a peripheral hæmorrhagic zone. The cut surface is dry, red in colour, and riddled with white nodules of varying size, the largest ones being 4 mm. across. The centre of all the larger nodules is distinctly softened. The organ weighs 845 gm.

J. H., aged 19, had been ailing for four to five weeks with typhoidal

symptoms, and was treated as suffering from typhoid, though Widal was absent. Ultimately tubercle bacilli were found in the sputum. Meningeal symptoms supervened, but no macroscopic tubercles were found in the meninges. Lungs, liver, thyroid, and cervical glands were affected.

P.M. Prof. Adami made the following note: 'The appearance of the tuberculous areas was extraordinary. It was as though the tubercles, after developing up to a certain good size, had suddenly been struck throughout their whole extent by a necrotic change, so that right to the outer border of each tubercle there was apparent caseation, with pycnotic nuclear remains scattered more especially through the peripheral portions of the tubercles.'

Stained by Gabbett's method, there were found numerous 'large, long, well-staining bacilli, somewhat thicker than normal, but otherwise quite characteristic and in other parts tending to be beaded. The great proliferation of the bacilli showed itself at the borders and outside the areas which histologically were seen to be of the nature of tubercles.'

Micro. Exam. Shows replacement of normal structure by large caseating areas. They possess cells with (pycnotic?) nuclei in large numbers. The remainder of the tissue is rich in coagulated exudate, and is very congested.

Ref.: E. 4097. R.V.H. 29.10.

PRESENTED by Dr. Adami.

43.361⁸ Tuberculosis of Spleen.

The organ is somewhat reduced in size, and is riddled with large, caseating foci. The surface shows coarse nodules, with a somewhat flattened exterior standing out from an otherwise smooth capsule. The cut section shows central breaking down of these foci, and characteristic retraction of the separating fibrous bands. The capsule is thickened with adhesions of old perisplenitis.

Old Museum specimen.

43.361⁹ Tuberculosis of Spleen. (Petri-dish Specimen.)

A slab of spleen studded with subacute tuberculous nodules. The capsule is thickened and shows adhesions. The nodules vary in size from a pin-point to 1.4 cm. in long diameter; they all show an ochre-yellow or pale-yellow centre, and a brilliant-red contour.

The remainder of the spleen is pale. The masses appear to be situated in the Malpighian bodies.

Ref. : E. 2365.

PRESENTED by Army Medical Museum.

43.361¹⁰ Tuberculosis of Spleen.

The specimen consists of a small slice of spleen, measuring 14×4.5 cm., and showing numerous small nodules of growth scattered through its substance. Several of these growths are subcapsular, but most are ill-defined, presenting a clear white centre and an irregular, much larger, brown-coloured zone, which blends off at the margins into the spleen pulp, which is homogeneous and dark in colour. In many cases the brown zone has minute brown spots in it also. The diameter of most of the tubercles is only 2-3 mm., but at one end there are larger mottled areas which present a large central whitish mass surrounded by a narrow brown zone.

Ref. : E. 4341.

PRESENTED by Prof. McCallum.

43.361¹¹ Spleen. Miliary Tuberculosis.

A slab from a slightly enlarged spleen (measuring $13 \times 5\frac{1}{2}$ cm.), containing some tubercles. The cut surface is bright red in colour and shows a few yellowish-white areas scattered through it, soft and caseating in the centres, and enclosed by bright-red lines. They measure 5 cm. in diameter and have slightly lobated edges. One is seen to come to the surface, and here has a wedge-shaped cross section. The Malpighian bodies are visible, but not enlarged.

The reverse side shows some hæmorrhagic infiltration of the pulp.

The spleen was surrounded by a dense mass of adhesions, which bound it to the thickened parietal peritoneum. The capsule was roughened and thickened. On its surface were several small rounded

yellowish areas as large as a split pea, having the appearance of coming to the surface from the splenic tissue beneath.

J. L., aged 49, died of miliary tuberculosis of the lungs; larynx, peritoneum, liver, spleen, pleura. There was chronic pleurisy with effusion. The bronchial glands were tuberculous. (A duplicate slab is mounted in a Petri dish.)

Ref. : E. 4072. M.G.H. 182.09.

PRESENTED by Dr. Maclachlan.

43.361¹² Multiple Tuberculoma of Spleen of Unusual Type.

Half of an enlarged spleen, measuring $19 \times 5 \times 7$ cm. The capsule is thick and is studded with numerous round elevations, varying in size from a hazel-nut to a pin-head, which are formed by nodules in the parenchyma, pushing forward from within and suggesting at first sight a new growth. The surface of these elevations is slightly umbilicated, greyish-white in colour, and they are dotted along their periphery with minute tubercles.

The cut surface is thickly sown with the same round nodules, which in some places have become confluent to form areas 5 cm. in diameter. They are of cheesy consistency and yellowish-white colour with hæmorrhagic core, and spring forward sharply above the intervening splenic tissue, which is deeply congested.

Mrs. D., mother of five healthy children, the youngest 7 months old. Abdominal tumour noticed for seven months, which gave no symptoms and was assigned by her to pregnancy. Examination previous to operation showed a tumour in the left side of the abdomen, appearing from under the margin of the ribs and extending down nearly to Poupart's ligament. The anterior border could be felt throughout, except where it disappeared under the ribs. Anteriorly it extended nearly to the umbilicus, and posteriorly could be felt in the region of the kidney. It was hard and firm, not fluctuating, fixed above and loose below. No urinary or intestinal symptoms. Splenectomy was performed Nov. 12, 1914. Some enlarged glands were seen behind the enlarged spleen, but were not removed. Abdominal and pelvic organs otherwise normal.

The enlarged spleen measured $20 \times 13 \times 5$ cm. and weighed 950 grm. Over the surface and throughout the pulp were numerous nodules, the size of a hazel-nut, of soft consistence and red colour, those on the surface showing a greyish centre.

Micro. Exam. of nodules showed a somewhat myxomatous structure. In this are numerous tubercles consisting of a small necrotic area surrounded by a zone of epithelioid cells. Giant cells are very numerous. Diagnosis: tuberculosis.

A guinea-pig was injected intraperitoneally with emulsion of spleen-pulp, but remained in apparent health, increased in weight, and showed no signs of disease when killed ten weeks later.

Ref.: W.G.H. 1086.13.

PRESENTED by Dr. Jasper Halfpenny and Dr. Sidney Peirce, Winnipeg General Hospital.

43.361¹⁵ Spleen. Senile, with Multiple Obsolete Tubercles.

Portion of a spleen whose capsule is wrinkled and presents a small number of round, convex, semi-translucent, lemon-yellow, hard, subcapsular nodules, which project from the surface. Peripheral congestion is hardly perceptible. The cut surface shows increased fibrous tissue and several similar nodules.

The spleen weighed 80 gm. and measured $7.6 \times 6.5 \times 2$.

Mrs. C. B., aged 72, had symptoms pointing to appendicitis for about six months. No history of tuberculosis in family, none during life in patient.

P.M. Appendicitis with perforation, fat-necrosis of mesentery and parietes, calcareo-caseous tuberculosis of lungs and peribronchial glands, arterio-sclerosis.

Micro. Exam. Showed normal structure; the vessels were slightly thickened.

See also Specimen No. 25.361.

Ref.: R.V.H. 109.08. E. 3418.

PRESENTED by Dr. Adami.

43.361¹⁶ Tuberculosis of Spleen. Multiple Infarcts.

Half a small spleen (9×5 cm.), showing a wedge-shaped area of white colour, slightly roughened on the surface, and marked out by a broad hyaline and not very sinuous line; a smaller focus occurs higher. The cut surface is chalky-white and very sharply defined; there is no area of redness around. The remainder of the cut surface is pale, and mottled with numerous minute Malpighian bodies.

The capsule is opaque and slaty in colour. There is slight puckering in the vicinity of the nodules ; there are no notches.

S. S., male, aged 11. Admitted May 2, 1910, with pain, swelling, and tenderness of wrists, elbows, and ankles, fugacious in character, purpuric eruption over whole body (Henoch's purpura), hæmaturia, and melæna. Later subacute nephritis developed ; œdema and ascites. A week before death meningeal symptoms, headache, internal strabismus, Kernig, stiffness of neck, vomiting. Died, comatose, June 18, 1910.

P.M. Tuberculous adenitis of peribronchial and mesenteric glands. Miliary tuberculosis of lungs, liver, spleen, and meninges. Solitary tubercles of cerebrum and cerebellum.

Micro. Exam. Miliary tubercles are seen within the Malpighian bodies. Some show well-marked giant cells ; others are commencing to caseate. The pulp is congested ; the Malpighian bodies are strikingly lymphoblastic.

Ref. : M.G.H., A. 10.106. M. 10.364. E. 4519.

PRESENTED by Dr. Rhea.

43.361¹⁷ Tuberculosis of Spleen. (Petri-dish Specimen.)

A slice of spleen showing several discrete rounded areas of pale colour, sharply demarcated from the remainder of the splenic substance. Their centres are softened ; the contours delicately lobate. The Malpighian bodies are just visible. The trabecular tissue is not prominent.

Mrs. M. G., aged 31. Admitted to M.G.H. May 18, 1907, with cough and symptoms of typhoid. June 14, inguinal glands became swollen. July 10, anterior part of right lower lobe of lung became consolidated. There were finally signs of general tuberculosis.

P.M. Generalized miliary tuberculosis of lungs, spleen, kidneys, meninges, peritoneum, and pleuræ. Chronic perihepatitis and perisplenitis. Tuberculosis of retroperitoneal and pelvic lymph-glands.

Micro. Exam. Malpighian bodies few in number, indistinct. Hyaline change in vessels. Pulp contains pigment-bearing cells. Fibrous tissue increased. Numerous small tubercles present, and one large caseous mass is demonstrated.

Ref. : E. 4470. M.G.H., A. 07.222.

PRESENTED by Dr. Rhea.

*Bovine Tuberculosis.***43.361²⁰ Spleen of Cow. Tuberculosis and Hyaloserositis.**

A portion of spleen whose surface is extremely roughened and irregular. The cut surface shows enormous thickening (1 cm.) of a large portion of the capsule by a formation of hyaline substance in which lamination can be detected. Flame-shaped streaks of bright yellow colour occur in the inner border. There are also two large cheesy yellow masses in the spleen substance, one of which shows central breaking down. One mass measures 2.25×2.75 cm.; the other much larger. The edges are bright red, and the non-softened part of the smaller mass has a similar hyaline appearance to the capsule. The spleen-pulp is scaly, dark in colour, and shows a few enlarged Malpighian bodies.

(A duplicate slab is mounted under a Petri dish.)

Ref. : E. 225.

PRESENTED by Dr. Adami.

.364 Lesions due to B. Mallei (Glanders).**43.364¹ Abscesses of Spleen in Chronic Glanders.**

Three fragments of a spleen whose capsule is smooth. The cut surface shows several abscesses of irregular contour and varying size. The largest slice presents in the middle an arborescent yellowish mass, with small round nodules intermingled and enclosed in a large zone of red colour. A wedge-shaped mass approaches the capsule at one end, and the two are connected by the aforesaid hæmorrhagic area. The smaller abscesses are also arborescent, but are clearly defined and have no surrounding zone. The Malpighian bodies stand out very distinctly as white specks with an enclosing dark zone identical in appearance with the Malpighian bodies of a sago spleen. (These gave the amyloid reaction.)

History. L. P. C., a farmer, aged 46, born in the Province of Quebec, always a hard worker. Habits were good and health robust. Never used alcohol in any form and never had venereal disease. Illness began in 1900 with localizing symptoms on forehead, and later on general symptoms appeared. He had been exposed to glanders in horses. Two months later a large abscess was opened in the thigh and then another in the leg, but the sinuses kept on burrowing. The facial lesions did not appear different even three months later, but after that began to heal in one place and track deeply in another. The same feature of healing and extension occurred in other lesions. Six months later he came to the R.V.H. and a diagnosis was then made. The skull was involved and the illness continued for two years. He subsequently died of intracranial disease.

P.M. Chronic glanders; multiple abscesses in glands, muscles, spleen, lungs, and liver; chronic local granuloma of the dura mater; compression of the brain; amyloid disease; acute fibrinous perihepatitis and perisplenitis; portal pylephlebitis; acute colitis; chronic parenchymatous with early interstitial nephritis.

The spleen was very large, weighing 620 grm., and rather soft. Its capsule was tense, dark red, and covered in places with adherent fibrinous lymph. Here and there on the surface were a few yellow elevations of dry, fibrino-purulent material the size of a dry pea.

On section the organ was intensely reddened and thickly studded with abscesses, varying in size from a pin's head to a filbert.

Micro. Exam. The walls of the sinuses and the sinuses themselves moderately full of blood. There was well-marked amyloid disease affecting almost exclusively the Malpighian bodies, and necrotic foci with poorly staining contents were seen.

Ref.: R.V.H. E. 4092b. *Studies from the Royal Victoria Hospital*, vol. ii, No. 1.

PRESENTED by Dr. G. D. Robins.

.37 Specific Inflammations due to Protozoa.**.372 Lesions due to *Treponema Pallidum* (Syphilis).****43.372¹ Spleen in Syphilis.**

A spleen, measuring $12 \times 6 \times 4\frac{1}{2}$ cm., and weighing 275 gm. The organ is moderately increased in size, and has an irregularly lobulated surface, due to contraction of the fibrous tissue. The notching is normal. The capsule is much thickened here and there (perisplenitis), showing a ragged surface. The cut surface is mottled with deep brown areas of intense congestion, and shows subdivision of the pulp by thick fibrous tracts; the consistence is firm. Malpighian bodies can only be made out here and there, but where present are enlarged. The spleen-pulp has been accidentally torn at the lower end.

J. E. H., aged 41, male. A case of long-standing aortic aneurysm. Syphilis had been contracted 19 years previously, and the aorta showed definite syphilitic disease, and the liver a diffuse cirrhosis.

P.M. Spontaneous rupture of aneurysm of aorta; old perihepatitis; old perisplenitis.

Micro. Exam. The organ appeared uniformly congested. No evidence of fibrosis in the pulp-tissue itself.

Ref. : R.V.H. 13.09. E. 3570.

PRESENTED by Dr. Klotz, February 1909.

43.372² Spleen in Syphilis. Megalosplenic Cirrhosis.

A very large spleen, weighing 1,000 gm., and measuring $20.5 \times 11.5 \times 9$ cm. The surface is diffusely opaque, especially over the outer curvature and near the upper pole, and is roughened also from the presence of adhesions to the surrounding tissues. Over some areas fine nodulation is visible. The capsule is tense, the organ rather flabby, the cut surface pale red. The Malpighian bodies are very indistinct; the connective tissue is not obviously increased (to the naked eye) owing to the hyperplastic condition of the pulp-tissue.

P. S., aged 43, admitted Sept. 12, 1911, died Oct. 3, 1911, complained of diarrhoea, abdominal pain, and distension, especially last six months. Patient took four glasses of whisky a day. No vomiting. Blood showed: reds, 4,240,000; whites, 5,400; polynuclears, 80%;

mononuclears, 4.5% ; large lymphocytes, 7% ; small lymphocytes, 7% ; mast-cells, 1.5%.

P.M. Unilobular megasplenic cirrhosis, hepatitis, and multiple gummata. Ascites, no jaundice ; chronic pericholecystitis, pancreatitis, and peripancreatitis. Thrombosis of portal vein and atypical ulceration of stomach wall with polyposis.

Micro. Exam. The capsule is much thickened and infiltrated with inflammatory cells. The trabeculæ are also markedly increased, large trabeculæ coursing throughout the section. These trabeculæ have a hyaline appearance and support tortuous vessels. Multiple hæmorrhages occur along the lengths of the thickened trabeculæ, and blood-pigment is deposited. Malpighian bodies are scanty and quite small ; the central vessels have thick walls and small lumina ; in some the centres of these collections are occupied by fibrous tissue. The cells are chiefly lymphocytes ; germ-centres are very numerous ; intermingled with them may be seen a few polymorphonuclear and endothelial cells. The peripheries are invaded by red blood-cells. The peri-Malpighian sinuses are much dilated and filled with red blood-cells and lymphocytes. The pulp sinuses are also dilated, and contain principally red blood-cells with endothelial cells and lymphocytes. Eosinophiles and polymorphonuclears are rarely seen. The pulp cords have undergone hyaline transformation in places owing to the replacement of the other cells by fibrous connective tissue.

Ref. : R.V.H. 148.11. E. 4734.

PRESENTED by Dr. Gruner.

.376 Lesions due to Hæmosporidia (Malaria).**43.376¹ Spleen in Malaria.**

A giant spleen, measuring $22 \times 17 \times 9$ cm. The edges are very rounded, and the colour is rather pale. The surface is smooth over the greater part of its extent, but at the upper pole it is roughened from a brownish deposit upon it. Two small round white nodules occur on the outer surface half-way down the organ.

The cut surface is rather pale and quite homogeneous in appearance. There is no macroscopic increase in the fibrous tissue, and there are no Malpighian bodies to be seen.

From a Chinaman with an obscure history of malaria.

Micro. Exam. The Malpighian bodies are very small. The pulp is loose in texture, and is crowded with plasmoid cells, pigmentophages and polynuclears. The channels are very wide. The pulp-tissue is excessively rich in pigment.

Ref. : M.G.H. 189.03. E. 975.

PRESENTED by Dr. Wyatt Johnston.

.5 CONSTITUTIONAL DISEASES. DISEASES OF METABOLISM AND INTOXICATIONS.

.51 Diseases of the Blood-forming Organs.

.512 Splenomegaly with Erythræmia.

43.512¹ Splenomegaly with Erythræmia (Osler's Disease). Chronic Perisplenitis with Multiple Infarcts.

A slice of a greatly enlarged spleen, 29 × 15 cm. in diameter, of very firm consistency and deep red colour. The cut surface shows marked increase, both of the pulpar tissue, which springs forward, and of the fibrous trabeculæ. Several wedge-shaped white infarcts lie along the posterior border, only one of these being visible on the surface placed anteriorly in the jar; they are of cheesy consistency, yellowish-white colour, spring forward sharply above the adjacent tissue, and are surrounded by a bright-red hæmorrhagic zone.

The capsule shows scattered patches of fibrosis, both over the infarcted areas and elsewhere.

From a case seen by Sir William Osler with Dr. Nathan Brice in Mount Sinai Hospital, New York, in 1910, and pronounced an atypical case of erythræmia.

Mrs. F., aged 58, born in Russia. Lived in United States 13 years. History of lues, malaria, alcohol. Illness began nine years before death with severe headache, vertigo, and pain in back. One year before admission, pain and tenderness on left side, under costal border. Examined in hospital in 1908, and spleen was found enlarged to level of anterior superior spine. Liver also palpable. Red blood corpuscles, 8,500,000 to 9,100,000 per c.mm.; Hb, 105 to 119%; poikilocytosis and anisocytosis (moderate); white blood corpuscles, 8,500 to 21,000 per c.mm.; polynuclears, 86%; myelocytes, 2%. In 1912 blood showed 8,500,000 red cells, 110% Hb, 34,000 leucocytes per c.mm. A few megaloblasts and many normoblasts.

Splenectomy was performed July 23, 1912. Two days later Hb 85%, red blood corpuscles 6,592,000, white blood corpuscles 44,000. Many 'blasts'. At time of operation ascites was present. There was no cyanosis, but skin was slightly icteroid. Wassermann negative. Died eight days after operation on August 1, 1912.

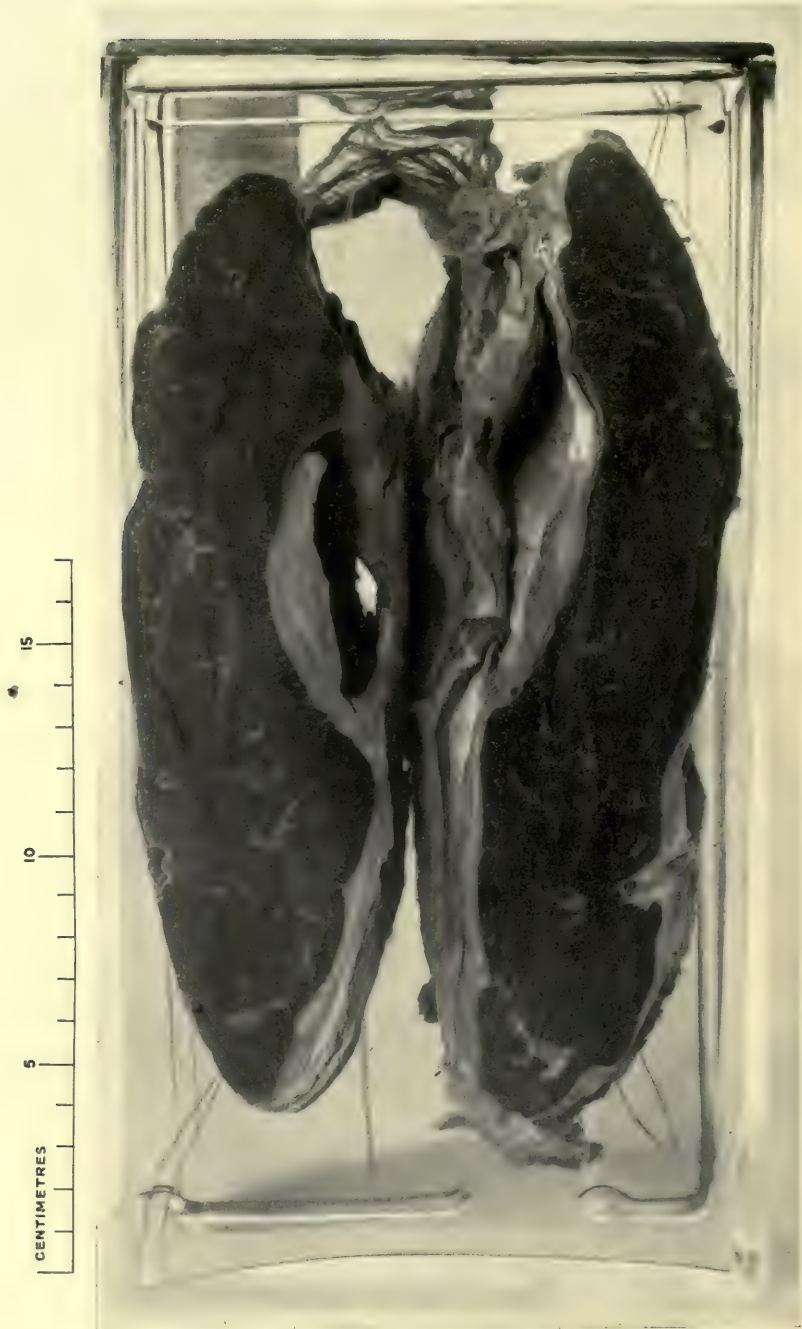P.M. Splenomegaly with erythræmia; cardio-renal degeneration with arterio-sclerosis. The enlarged spleen measured 31 × 16 × 8 cm. and weighed 2,750 grm.

Ref.: New York Post-Graduate Hospital, No. 8291, *Journ. Med. Res.*, 1914.

PRESENTED by Dr. O. S. Hillman, Post-Graduate Hospital, New York.




PLATE XI



43,513¹ SPLEEN FROM BANTI'S DISEASE, PRIMARY SPLENOMEGALY,
WITH CIRRHOSIS HEPATIS. HYALOSEROSITIS OF CAPSULE

Note huge size of organ and fibrosis of cut surface

Dr. Wolbach

.513 Primary Splenomegaly. Banti's Disease. Splenic Anæmia. Gaucher's Disease.

43.513¹ Splenomegaly in Cirrhosis of Liver (Banti's Disease). Hyaloseritis and Abscess of Spleen.

A greatly enlarged spleen, measuring $24 \times 14 \times 5$ cm., whose surface is composed of a greatly thickened, opaque, hyaline substance, to which are adhering shaggy pieces of muscle (diaphragm) and other tissue. Notches are not visible. Occupying the middle one-third of the outer border is a cavity within the layers of the thickened capsule, which at the post-mortem contained 250 c.c. of thick yellow pus.

The cut surface shows a dense cartilaginous, partly laminated capsule of 0.5 cm. thickness (varying a little). The cut surface of the spleen is dark in colour and shows slightly enlarged Malpighian bodies and prominent trabeculæ.

D. O., male, aged 35, admitted to the M.G.H. Feb. 27, 1909, with history of daily rigors for past 15 days, and complaining of pain in the stomach. Examination showed intense jaundice, chronic bronchitis, arterio-sclerosis, enlarged heart; liver and spleen enlarged and hard. Fever, chills, and perspiration at irregular intervals continued. On March 16 fluid developed in the abdomen.

Stained slides from the blood showed organisms resembling *plasmodium malariae*, but these were only found in specimens stained by Wright's triple method. Progressive anæmia and weakness, with increased ascites. On July 1, 4,800 c.c. of fluid were withdrawn from the abdomen; spleen as before, but liver not palpable. Died June 7, 1910.

P.M. Chronic suppurative cholecystitis and cholangitis; splenomegaly, with chronic perisplenitis and perisplenic abscess; chronic fibrous pleuritis; cirrhosis of the liver.

Micro. Exam. The capsule is greatly thickened by hyaline-looking fibrous tissue which is poor in nuclei. The trabeculæ are also greatly thickened, leaving very little proper splenic tissue. There are but few Malpighian bodies, and they are small in size and contain few germ-centre cells. The reticulum of the pulp is conspicuous and red cells are relatively sparse. Few phagocytes or endothelial cells or pigmented cells or eosinophiles are to be seen.

Ref.: E. 3895. M.G.H. 125.09.

PRESENTED by Dr. Wolbach.

43.513² Spleen in Banti's Disease.

A moderately enlarged spleen, measuring $17 \times 11 \times 4.5$ cm., with a smooth pale surface, save near the upper pole, which shows a few tags of lymph. At the junction of the middle and upper half is an irregular patch of hyaloseritis, 4.5×4 mm. across. The thickening of the capsule here is 2 mm. The cut surface is very pale and just shows a faint white mottling with Malpighian bodies. At the time of removal the spleen was described as fibrosed.

C. B., male, was ill for one year before death, but had symptoms for three years. There were splenic enlargement, anæmia, weakness, jaundice, ascites, and pain over the splenic region. There were periods of improvement, but a progressive downhill course and death from asthenia.

P.M. Diffuse fibrosis of spleen; enlarged spleen; cirrhosis of liver.

Micro. Exam. The capsule is considerably, and the trabeculæ moderately, thickened. A striking feature about the splenic tissue is the abundance of pulp-cells (which are atypical in form) and the abundance of interstitial deposit of fibrous material. The latter contains many spindle-shaped cells. The endothelium of the pulp is not conspicuously altered, although in many cases the cells are spindle-shaped in type. The blood-channels are dilated. There are a few pigmented cells. The Malpighian bodies are almost entirely lost; a few areas of lymphoid-celled formation occur close to the trabeculæ, but are ill-defined in outline and very small in size. They are enclosed in an excess of fibrous tissue. Eosinophiles are not seen.

Another section shows very great thickness of the capsule, and the spleen substance immediately beneath it shows very conspicuous dilatation of the blood-vessels, in which lie eosinophile cells along with ordinary blood-cells. In this section there is a sprinkling of brown pigment, and the fibrosis of the pulp is even more marked. The Malpighian bodies are easily seen, but they are scanty, small, and ill-defined.

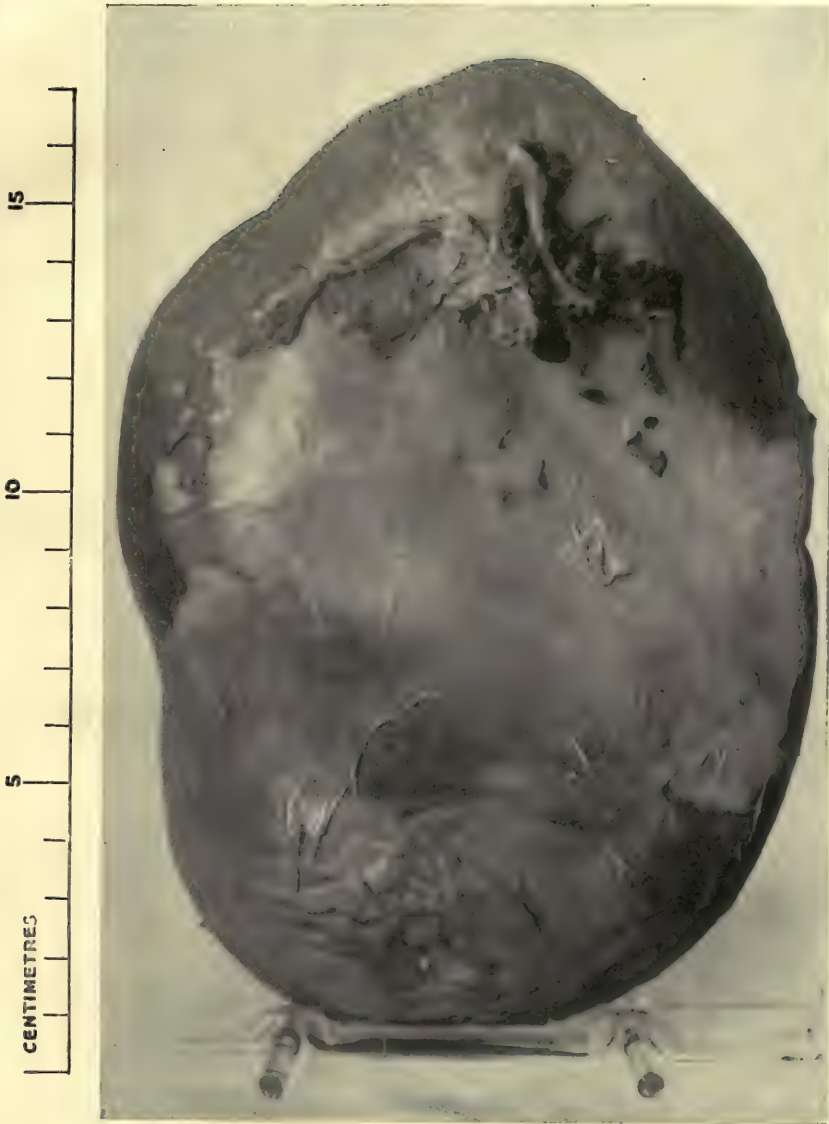Ref.: Entry No. 3439.

PRESENTED by Dr. Hamilton.

43.513³ Spleen in Banti's Disease. Hyaloseritis.


Half of a greatly enlarged spleen. The organ is marked on its outer surface by a large irregular mass of thickened capsule, having a bright ochre-yellow colour; half-way from the two extremities is a paler area in which spicules of calcified matter are present. The outlines of this area of hyaloseritis are for the most part

PLATE XII



43.513³ SPLEEN IN BANTI'S DISEASE. HYALOSEROSITIS

Dr. Gruner



clearly marked off by a bluish line of congestion ; but at the lower end it blends imperceptibly with a generally opaque capsule, in which, however, a few tiny irregular prominences are seen. There is no notching and the outlines are rounded ; attached to the upper end is a broad tag of adhesions.

The cut surface originally had a deep maroon colour, and was apparently homogeneous throughout (as it is now). No Malpighian bodies can be seen. The fibrous trabeculæ are slightly conspicuous.

A male Italian, aged 50, was admitted to R.V.H. August 16, 1912, for ascites and epigastric pain ; had been ill for three weeks ; he had been six years in Canada ; had a fever of some kind at 25 ; the abdomen was tapped many times. The clinical diagnosis was atrophic cirrhosis. Died Oct. 18th.

P.M. Multilobular cirrhosis, partly biliary ; subperitoneal hæmorrhages ; muscle degeneration of heart ; focal atheroma of aorta ; leucoblastic marrow.

Micro. Exam. A definite increase in the connective tissue throughout the organ ; there is very marked fibrosis of the coats of the central arteries of the Malpighian follicles.

Ref. : E. 5341. R.V.H. 146.12.

PRESENTED by Dr. Gruner.

43.513¹⁰ Gaucher's Splenomegaly.

A small slab of an enlarged spleen with a smooth capsule, showing a number of pinhead-sized brownish-coloured spots on a pale background. The cut surface tends to bulge. The spots are evidently altered Malpighian bodies, and recall the appearance of amyloid disease.

From a boy, aged 4½ years. Admitted to the Mount Sinai Hospital on Feb. 26, 1912, because of an accident. Enlargement of the spleen and liver was found as well as altered structures. The blood examination showed : red cells, 2,208,000 ; white cells, 500 ; Hb, 35%. No abnormal cells. Polynuclears, 70 ; large lymphocytes, 25 ; small lymphocytes, 3 ; mononuclears, 1 ; myelocytes, 1. No normoblasts, slight poikilocytosis and anisocytosis. Splenectomy was performed on March 1, 1912, and death occurred within 24 hours. Other members of the family apparently had the same disease.

P.M. Enlarged tracheo-bronchial nodes ; thymus weighed 6.8 grm. No ascites. Enlarged periportal nodes, and intestinal follicles. Enormous enlargement of all mesenteric and retroperi-

toneal lymph-nodes. Marrow of tibia bright red with small white dots.

Micro. Exam. Note presence of iron-containing pigment and large multinuclear cells in a characteristic cytoplasm. In early cases, large phagocytic cells arise from the germ-centre cells, and become swollen and vacuolated. With the low power, one notices many large, round, or oval spaces with well-defined outlines. These are the venous tissues, each of which is more or less distended with blood. With the high power a peripheral layer of large cells is seen closely united to the wall and apparently arising from the endothelium of the sinus. Some of the cells are detached and are seen lying free in the lumen of the sinus surrounded by blood cells. The sections also contain a large number of similar alveolar spaces filled with the same type of large cells, but without any endothelial lining. The Malpighian bodies are of enormous size. In many the small deeply staining tingible bodies of Flemming are found. These are contained in large cells, which resemble the other large cells in size and shape. Many have nuclei and also contain the non-stainable pigment granules described by Flemming. These cells have all the appearances of phagocytes. Throughout the sections are mononuclear cells with eosinophile granulations. These are somewhat larger than the lymphoid cells, and the nucleus is often small and compact. Others have a larger vesicular nucleus and resemble typical myelocytes.

The reticulum encircles the Malpighian bodies in a very regular and uniform manner, the individual fibres being short and delicate, as a rule. Three or four layers of fibres, somewhat separated from each other, are usually seen. Fibres are also found between the lymphoid cells of the Malpighian body and in the germ-centre, but always in small amount. The fibres do not appear to be connected with either the peculiar cells described in the germ-centre, or the large cells situated between the lymphoid cells, though it must be admitted that such a relation is possible.

There are no areas of degeneration, necrosis, or hæmorrhage in the spleen, and no evidences of a tuberculous process.

Ref.: 'The Pathology of Primary Splenomegaly,' *Journ. of Exper. Med.*, xvi, 1912, No. 6, p. 797.

PRESENTED by Dr. Mandlebaum.

.514 Leukæmia.**43.514¹ Enlargement of Spleen in Leukæmia.**

A moderately enlarged organ, measuring $15 \times 10 \times 3$ cm. in diameter, of normal contour, the notches preserved, but shallow. The surface is somewhat wrinkled and is pale in colour (action of Sappey's fluid), with a few punctiform mottlings. A band of perisplenitis crosses over the lower third. The cut surface is homogeneous and shows nothing. There is no evidence of the accompanying leukæmia, and the organ is kept to show that a relatively small spleen may occur in this disease.

Micro. Exam. Shows thickening of the trabeculæ. The pulp has a loose structure, but the tissue stains so poorly that no cellular details can be made out.

Old Museum specimen.

*Spleno-medullary Leukæmia.***43.514² Splenomegaly in Spleno-medullary Leukæmia.**

An enormously enlarged organ, measuring $26 \times 15 \times 9$ cm., of very firm consistency, normal contour preserved, notches distinct. The organ is mottled by large ill-defined pale areas due to multiple infarctions of varying size. The capsule is irregularly thickened and bears a few adhesions.

A. S., male, aged 11. Leukæmia of two years' duration. Abdominal swelling first noticed October 1897. Headaches, dizziness, epistaxis followed, and increasing abdominal enlargement. Admitted Feb. 27, 1899, emaciated. P. 128, R. 38, T. 99.4° . Dyspnoea, slight cyanosis, abdomen immensely distended. A large mass, having an edge with four distinct notches, occupied the whole left half, being palpable from ninth left costal cartilage to 2.5 inches to the right of umbilicus, thence to pubes. Superficial glands slightly enlarged. Blood examination March 21, 1899, was: Red blood cells, 2,080,000; leucocytes, 284,000; Hb, 23%. On July 4, 1899, red cells, 955,000; leucocytes, 460,000; Hb, 25%. Many myelocytes.

P.M. Superficial abdominal veins dilated. Spleen and liver almost filled abdominal cavity. Spleen firm, weight 2,783 grm. Measured $31 \times 18 \times 9.5$ cm. Irregularly congested, several large white infarcts. Liver also much enlarged, pale, soft, and fatty. Slight ascites. Enlarged retroperitoneal glands.

Micro. Exam. Sections in this case are remarkable for the great numbers of eosinophile myelocytes which are present everywhere in the capillaries, vastly outnumbering other forms of leucocytes.

Ref. : R.V.H. 62.99. Entry No. 553.

PRESENTED by Drs. Stewart and Adami.

43.514³ Splenomegaly in Leukæmia.

A greatly enlarged, elongated organ, of firm consistency, the capsule irregularly thickened with tags of adhesions. On the outer and upper surface there is a large fibrous infarct with cystic centre. Other infarcts of smaller size are visible scattered over the surface of the organ.

E. D., female, aged 25. First symptoms, low fever and chills, set in in June 1897. 'Growth in abdomen' (enlarged spleen) was noticed in July 1897, and increased steadily. Admitted June 27, 1898. The spleen was palpable at the brim of the pelvis, having a distinct notch in its right margin. Laparotomy was performed July 1, and revealed an enormously enlarged spleen, normal in colour and of firm consistency. Death two days later.

P.M. Hyperplasia of bone-marrow. Slight hyperplasia of cervical, axillary, and inguinal glands. Spleen reached slightly to right of median line and to within 3 inches of pubes. Weight 2,065 grm. Measurements : 37.5 × 19.5 × 5.5 cm. On section, firm, pale, with several infarcts. The splenic veins were very large.

Ref. : E. 4. R.V.H. 51.98.

PRESENTED by Dr. Adami.

43.514⁴ Spleen in Myelogenous Leukæmia with Rupture of Softened Area.

The spleen is enormously enlarged, measuring 27 × 16 × 9 cm., with a smooth surface, showing notches only to a slight extent : the surface is mottled in an irregular fashion. At the lower pole is a fluctuating mass, containing bloody fluid, and having a soft pulpy substance. The upper half of the organ is hard and firm, showing some white infarcts ; it has burst in two places.

Farmer's wife, aged 38, from north-west Ottawa. First noticed swelling four months before death, which kept growing upwards and gave rise to labour-like pains ; nausea and vomiting were present.

She had had several miscarriages. Was never further south than Smith's Falls, Ontario. Father and mother both had paralysis; brother died of phthisis. Temperature normal on admission, but rose later. Unconscious two days before death, with paralysis of face on right side. There was blood in the stools.

Blood Exam. Red cells, 5,664,000; hæmoglobin, 85%; whites, 20,700. Differential: Polymorphonuclears, 60%; lymphocytes, 0·8%; large mononuclears, 1%; eosinophiles, 4·8%; mast-cells, 2·7%; neutrophile myelocytes, 30%; other myelocytes, 13%.

Micro. Report. Blood sinuses not visible. The pulp is made up of closely aggregated large cells, with large, well-staining nuclei; occasional giant cells with several nuclei are seen; small lymphocytes are only irregularly distributed about some of the vessels. Bands of necrotic tissue stretch through the section, giving an appearance of infarct; there is slight congestion of the periphery of these areas. With the low power the size of the cells in the non-infarcted portion is most striking, and gives rise to an appearance not unlike that of round-celled sarcoma. Evidence of blood destruction is not seen; the protoplasm of the large cells is not granular. There is also a white infarct in the liver.

Ref.: Entry No. 3088.

PRESENTED by Dr. Mohr, Ottawa.

Lymphatic Leukæmia.

43.514¹⁰ Spleen in Acute Lymphæmia.

A very large spleen, weighing 900 gm. and measuring 20×15×8 cm. The edges are rounded; there are four deep notches on the anterior border. The surface is smooth and pale, and the capsule is tense. The cut surface is very pale and fleshy in appearance. The Malpighian bodies are invisible, as also the trabeculæ. The pulp is fleshy in appearance but rather diffluent. The organ is absolutely normal exteriorly.

The patient was a dentist who had only been ill for two weeks with pain in the abdomen and headache. Bruises appeared all over the skin.

P.M. Hæmorrhagic purpura. Petechial hæmorrhages: subpleural, peritoneal, subepicardial, subendocardial, intramuscular, in the papillaries of heart, omentum, and all along the track of bladder and appendix. Enormously enlarged mesenteric and retroperitoneal glands.

Micro. Exam. Shows diffuse lymphadenoid change. There is a hyaline change in the reticulum with desquamation of the

endothelium lining the sinuses. The pulp-cords are ill defined, are rich in cells, and contain megakaryocytes and eosinophiles.

See also Specimen No. 42.514.

Ref. : E. 4957. R.V.H. 47.12.

PRESENTED by Dr. Gruner.

43.514¹¹ Giant Spleen in Acute Lymphatic Leukæmia.

An extremely large spleen, measuring $29 \times 16 \times 8$ cm., and weighing 1,820 gm. Its surface is smooth, the edges are rounded, and the consistence is firm. There are no adhesions. The capsule is tense, and the organ pinkish in colour. The cut surface bulges and shows apparent homogeneity and pale colouring. The Malpighian bodies are not to be seen, nor are the trabeculæ conspicuous.

D. B., male, aged 44. An Italian labourer, admitted to the R.V.H. for pain in the upper abdomen of 20 days' duration. There was slight icterus. Glands everywhere large, hard, movable. Blood : 2,040,000 reds ; 334,000 leucocytes. Albuminuria. Temperature, 104° . Death from cerebral hæmorrhage on July 17, 1912.

P.M. Acute lymphatic leukæmia with purpura hæmorrhagica. Hæmorrhages : subepicardial, subendocardial, omental, renal, mesenteric, stomach, intestine, subpleural, hæmolymp glands.

Micro. Exam. The normal structure is entirely lost. Differentiation of Malpighian bodies cannot be made out. The whole tissue appeared like pulp, but is rich in lymphoblastic cells of anomalous form.

See also Specimens Nos. 42.514², 41.514¹.

Ref. : E. 5207a. R.V.H. 100.12.

PRESENTED by Dr. Gruner.

43.514¹² Spleen in Lymphatic Leukæmia.

An enormously enlarged spleen, measuring 26×16 cm., with normal notchings and a perfectly smooth external surface of uniform colour. The cut surface is dark red, mottled with the much enlarged Malpighian corpuscles. One red infarct is seen.

Male, aged 35, was in hospital in 1904 with fever and enlarged spleen, diagnosed as typhoid fever. In 1906 had a similar attack, which proved to be lymphatic leukæmia, with a white-cell count of 106,000. Before death in 1908 red cells were 1,120,000, whites 385,000, Hb 22%.

Micro. Exam. The capsule is only slightly thickened and the trabeculae are inconspicuous. The normal structure of the spleen is practically lost, owing to the replacement of the pulp-tissue by cells with round trachychromatic pachychromatic nuclei of almost regular size. They are intermingled with red blood-cells, and are very similar in appearance to the cells composing the Malpighian follicles, within which there is active mitosis. Proliferating endothelial cells are seen in the vicinity of these follicles. Few phagocytes occur. There is no evidence of red-cell formation.

See also Specimen No. 42.514¹.

Ref. : M.G.H., A. 08.79. E. 3530b.

PRESENTED by Dr. Finley.

43.514¹³ Spleen in Lymphatic Leukæmia.

A massive spleen, measuring $24.5 \times 16.5 \times 5.5$ cm., and weighing 1,510 grm., having a pale colour, very smooth surface, and very rounded edges with three deep notches. The capsule is tense. There is ill-defined mottling with purple.

The cut surface is about homogeneous in texture, pale purple in colour. Follicles cannot be made out with certainty.

A. A., male, aged 33. Admitted to M.G.H. April 29, 1910, for general weakness, shortness of breath, and swelling of legs and neck. A swelling had been noted in the groin for 12 months. The left side of face became swollen three months later, with pain and tenderness. The swelling then became differentiable into separate glandular masses. Six weeks ago had 'grippe'. Noticed shortness of breath one month ago.

P.M. Marked general glandular enlargement. Enlarged spleen and liver. Active bone-marrow.

Micro. Exam. Shows loss of differentiation of structure, the whole tissue being composed of round cells of varying size with no structural arrangement noticeable. They are the size of mesolymphocytes, myelocytes not being noticeable. A number of eosinophiles and a large number of pigmentophages are present.

Ref. : E. 4467. M.G.H., A. 10.92.

PRESENTED by Dr. Rhea.

.515 Hodgkin's Disease.**43.515¹ Spleen in Malignant Granuloma.**

A spleen of medium size, weighing 400 grm., and measuring 17.5 × 11.5 × 4.5 cm., with rounded edges and smooth surface, mottled with fine reticulation, purple-red in colour. The cut surface is very dark red and granular owing to the diffuence of the pulp. The Malpighian bodies are easily seen; the trabeculæ, however, are not conspicuous. There are no tumour nodules. The organ is diffuent.

N. J., male, aged 27. Admitted July 3, 1911, died Nov. 19, 1911, complaining of enlargement of glands in neck and axilla, which began two years ago. X-ray treatment. History of gonorrhœa. Blood, Hb, 22.4%; polynuclears, 82.5%; transitionals, 4%; large mononuclears, 10%; lymphocytes, 3%; mast-cells, 0.5%.

P.M. Malignant granuloma of superior mediastinal, cervical, axillary, and lumbar glands (thymic in origin); Hodgkin's disease; invasion of dorsal spine and root of left lung; compression of spinal cord; red diffuent bone-marrow; hypostatic pneumonia.

Micro. Exam. The capsule is slightly thickened and is adherent to the underlying tissue. The trabeculæ are conspicuous, and appear as thickened bands throughout the section; some of them have a distinctly hyaline appearance. The Malpighian bodies are scanty in number and small, their peripheries blending imperceptibly with the surrounding pulp-tissue. The central vessels of these bodies are thick-walled and slightly tortuous. In the wall of one a small hyaline mass with serrated edges is seen; some of them are filled with blood, while others are quite empty. The surrounding cells are chiefly of the large lymphoid type. Germ-centre cells are very scanty. No evidence of polymorphonuclear or eosinophiles is seen. The edges of these collections are all invaded with red blood-cells. In the pulp the sinuses are engorged with blood, in which may be seen, as well as red cells, numerous polymorphonuclear leucocytes, eosinophiles, and small lymphocytes, together with a few vacuolated and swollen endothelial cells; some of the endothelials are pigment bearers. Germ-centres are more numerous here. Many macroplasma cells occur in the pulp-tissue, especially in immediate proximity to the smallest branches of the splenic artery.

Ref.: E. 4765. R.V.H. 162.11.

PRESENTED by Dr. Gruner.

43.515² Spleen in Hodgkin's Disease.

A slice of spleen, showing a few minute foci of disease scattered through it. Two occur with a red limiting line.

Male, aged 27. Ill for nine months with fever and swollen lymph-glands.

P.M. Combined tuberculosis and Hodgkin's disease. Changes in liver, spleen, pancreas, femur, and retroperitoneal lymph-glands.

See Specimens Nos. 41.515¹, and 42.515², and under Liver and Pancreas.

Micro. Exam. Tubercles with giant cells and nodules of new-formed tissue having structure of granuloma malignum.

Ref. : E. 5097.

PRESENTED by Dr. de Josselin de Jong, Rotterdam.

43.515³ Spleen in Hodgkin's Disease.

A portion of a spleen containing numerous cream-coloured nodules in its substance. The nodules have a delicately lobulated contour, are raised above the surface, and are traversed by reddish lines in some instances ; others are breaking down in the centre.

No history.

See also Specimen No. 42.515³, and under Liver.

Micro. Exam. The Malpighian bodies are diffuse and large. The pulp is loose in texture, and the blood-channels very large in some places. The pulp and trabeculæ have undergone a hyaline change ; pigment granules are numerous. There are several foci in the centres of the hyaline zones which are constructed very similarly to the centres of tubercles.

Ref. : E. 4880b.

PRESENTED by Dr. de Josselin de Jong, Rotterdam.

43.515⁴ Spleen in Hodgkin's Disease.

Portion of spleen showing a number of white nodules of varying size scattered through its substance. Some show slightly lobulated edges and central softening. The others are quite round. They stand out in marked contrast with the splenic pulp.

Female, aged 23. Became ill in September 1907, with fever and cough. Von Pirquet negative. No tubercle bacilli in sputum. Marked anæmia. Died August 1908.

P.M. Many small and large tumours (Hodgkin's disease) in lungs, liver, spleen, lymph-glands, kidneys, and pancreas. Cavæ injected with tumour mass. No trace of tuberculosis. Hodgkin's disease.

Micro. Exam. The section shows several granulomatous areas in which fibrous tissue radiates from a centre. Eosinophiles infiltrate between the fibres in large numbers. A few giant cells occur.

Note. The student will find it worth his while to compare the sections of the preceding three of the .515 series with this.

See also Specimens Nos. 42.515⁴, and under the Lung, Liver, Pancreas, and Kidney.

Ref. : E. 5096c.

PRESENTED by Dr. de Josselin de Jong, Rotterdam.

43.515⁵ Spleen in Hodgkin's Disease.

Two portions of spleen showing several small nodules within the substance. They are ill-defined in outline and of a yellowish tinge. Foci of congestion seen here and there.

F. H., aged 48, married, 7 children, 1 abortion. Always healthy previous to onset of present illness. December 1910 complained of always feeling tired. Temperature elevated, liver and spleen enlarged. Died March 20, 1911.

P.M. Hodgkin's disease ; granulomata in liver, spleen, kidneys, pancreas, and retroperitoneal glands. Weight of liver 2,200 gm., of spleen 600 gm. No nodules in lungs.

Micro. Exam. The Malpighian bodies are poorly shown. The fibrous tissue is very scanty. The pulp is œdematous and very rich in pigmentophages, as well as in free pigment, which appears in the form of coarse flakes of varying size. There are several granulomatous deposits containing large epithelioid cells. The pigment is scattered irregularly through the deposits.

See also Specimen No. 42.515⁵, and under the Liver, Pancreas, and Kidney.

Ref. : E. 5098b.

PRESENTED by Dr. de Josselin de Jong, Rotterdam.

.516 Pernicious Anæmia.**43.516¹ Spleen in Pernicious Anæmia.**

Half a moderately large spleen, measuring $14.5 \times 7.5 \times 2.5$ cm., weighing 215 gm. It is pale and has a smooth capsule. There are two notches. The cut surface is pale, and shows an abundance of fibrous trabeculæ. The Malpighian bodies are not easily seen.

A. T., female, aged 34. Admitted to the R.V.H. Nov. 27, 1912, with signs and symptoms of severe anæmia of six months' duration.

Nov. 30th, reds, 1,270,000 ; whites, 1,800 ; Hb 20%

Dec. 8th, ,, 780,000 ; ,, 2,700 ; ,, 10%

Dec. 16th, ,, 970,000 ; ,, 3,400 ; ,, 10%

Died with multiple hæmorrhages Dec. 16.

P.M. Cryptogenetic anæmia ; fatty degeneration of organs. Hæmosiderosis of liver. The spleen was moderately enlarged. Its outer surface showed moderately conspicuous Malpighian follicles and a relative increase in the amount of fibrous tissue. The pulp was rather soft. Notching was natural.

See also Specimens Nos. 42.516¹, 37.63.

Micro. Exam. The chief change in this section is the overgrowth of the stroma cells with hyaline inundation into the substance of the pulp-cords. The result is a conspicuous prominence of the blood-channels. Endothelial cells are met with here and there. The Malpighian bodies are for the most part atrophied.

Ref. : E. 5375. R.V.H. 174.12.

Canadian Practitioner and Review, March 1912.

PRESENTED by Dr. Gruner.

43.516² Spleen in Aplastic Anæmia.

A greatly enlarged spleen, weighing 530 gm., and measuring $18.5 \times 12.5 \times 5$ cm. The organ is dark red and fairly firm. It has three shallow notches anteriorly ; the surface is smooth and the capsule is wrinkled. It is perfectly normal exteriorly. Cut surface presents a deep-red colour, mottled with pinhead-sized nodules. One large greyish lymphoma was seen. There are one or two tiny infarcts in the substance of the organ, and a large infarcted area (about 2 cm. on surface) half-way along its length. The cut surface is flat, tending to convexity, and the pulp is fairly firm.

H. W., male Jew, aged 28. Family and personal history good. Gonorrhœa seven years ago. Five months before death he developed

a few small pustules on fingers of left hand, which disappeared on treatment. After a short holiday returned to work, but was easily tired and not up to par. On Sept. 9, 1911, another small pustule on one finger; temperature 99° to 100° ; spleen palpable. Examined by Dr. Hardisty on Sept. 14th, pale but well nourished; shotty glands in groin; heart somewhat enlarged with systolic murmur at base; liver palpable just below costal margin, spleen three to four finger-breadths below margin; very hungry; constipated; Widal negative. Blood: Hb, 50%; white blood cells, 5,300; red blood cells, 4,340,000; lymphocytes, 86.6%; polymorphonuclears, 12%; eosinophiles, 1.5%. Drenching night-sweats; rather dyspnoic on slight exertion. Sept. 30th, Hb, 33%; white blood cells, 5,500; red blood cells, 2,520,000; lymphocytes, 90.4%; one nucleated red cell seen. Admitted to R.V.H.; temperature 102° , axillary glands just palpable, slightly more so on left side (site of infection). Appetite enormous; blood-culture negative. Oct. 14th, red cells 770,000; improved slightly under arsacetin and cholesterin. Consolidation of left lung. End of November, ascites, left pleurisy with effusion, liver and spleen increased; white cells 9,800, 77% being lymphocytes. Signs of loss of compensation developed and small subcutaneous ecchymoses appeared. He sank gradually and died Jan. 16, 1912.

P.M. (Spleen, liver, and rib only examined.) Multiple infarcts and diffuse fibrosis of spleen. Fatty infiltration, intralobular hæmorrhages, and focal necrosis of liver. Bone-marrow atrophic with some mucoid change of interstitial tissue; cellular elements proper (chiefly lymphoid) varying little in size. Megakaryocytes scanty, eosinophiles absent; no evidence of erythroblastosis.

A full study of this case is published by Dr. Hardisty, R.V.H. *Bulletin*, No. 2, 1912.

Micro. Exam. The trabeculæ are unduly conspicuous and present a hyaline appearance in some cases. The pulp is rather atrophic. The Malpighian bodies are seen with difficulty, owing to their small size, and to the degenerative changes present in many of them. The central vessel is sometimes much thickened, sometimes converted into a hyaline-looking structure. The differentiation of the pulp is entirely lost in the necrotic areas which are of the nature of infarction. In the other sections the pulp-tissue is fibrosed, the sinuses being characterized by thickening of their walls, and swelling of their lining epithelium. The pulp cells are chiefly small lymphoid cells with swollen endothelial cells intermingled. Small infarctions occur in section. Diagnosis: Multiple infarcts. Diffuse fibrosis. Changes indicative of Banti's disease.

Ref.: E. 4871. R.V.H. 8.12.

PRESENTED by Drs. Hardisty and Gruner.

43.516³ Spleen in Pernicious Anæmia.

The spleen measures $13 \times 6.5 \times 4$ cm., and weighs 175 gm. The organ is slightly enlarged; the edges show deep notches on the anterior part, nearly splitting a lobule off; also a small notch exists on the posterior surface. The organ was flabby. The surface is mottled with tiny opaque pinhead-sized areas which are sub-peritoneal. There are some shaggy adhesions behind. The cut surface shows the Malpighian bodies clearly, and slight increase of the trabecular tissue.

R. S., male, aged 42, was admitted to the R.V.H. in November 1910, suffering from weakness, anæmia, shortness of breath, &c., which had existed 14 months. No tuberculosis, cancer, or rheumatism in the family. Blood: red cells, 940,000; white cells, 2,000; Hb, 16%; nucleated reds common; poikilocytosis; only 2 myeloblasts seen. Death was preceded by usual symptoms.

P.M. Hæmorrhages in pericardium; fatty heart, liver, and kidneys. The bone-marrow was pale.

Micro. Exam. Shows the capsule to be greatly thickened, but the trabeculæ are not thicker than normal. The Malpighian bodies are numerous, are ill-defined and irregular in size and shape. The central vessel is normal. There are many mitotic figures in the germ-centres, but there are other places where there is hyaline change. Eosinophile cells are numerous. The splenic channels are conspicuous and contain many large exfoliated endothelial cells with large nuclei, many of which exhibit mitotic figures. The elastic tissue is normal in amount. There are no nucleated red cells.

Ref.: E. 4480. R.V.H. 156.10.

PRESENTED by Dr. Gruner.

.53 Diseases due to Autochthonous Poisons of Organic Nature.

.531 Acute Yellow Atrophy.

43.531¹ Spleen from Acute Yellow Atrophy.

An organ of moderate size (10 × 3 cm.), of deep-red colour and mottled appearance, not showing Malpighian bodies. The consistence is very flabby.

From a girl aged 18, dying of acute yellow atrophy of the liver.

P.M. Acute yellow atrophy of liver; fatty kidneys; congestion of spleen; subperitoneal, retroperitoneal, subepicardial, and sub-endocardial hæmorrhages, and hæmorrhage into pelvis of kidney. Spleen slightly enlarged, weight 120 gm.

Micro. Exam. The Malpighian bodies are few. Blood-channels are enormously dilated and show desquamation of endothelium.

Ref.: E. 1474. M.G.H. 55.05.

PRESENTED by Drs. Armstrong and Gillies.

.6 RETROGRESSIVE CHANGES.**.61 Atrophy.****43.61¹ Atrophy of Spleen.**

A small spleen presenting the normal outline and surface. There is a notch on either side. The capsule is smooth and tense. The edges are sharp.

Ref. : A.M.M. 3184. E. 1924.

PRESENTED by Army Medical Museum.

43.61² Senile Atrophy of Spleen.

A very small organ, 7.5×5 cm. The cut surface shows excess of fibrous tissue. The capsule is much wrinkled.

Old Museum specimen.

43.61³ Atrophy of Spleen.

A small spleen of flattened shape, measuring 8×6.5×3 cm. The capsule is greatly wrinkled and shows one or two tags of fibrin. There is only one notch at the lower end. The cut surface has a homogeneous appearance. The white colour is due to initial preservation in bichloride.

Ref. : A.M.M. 2484. E. 1872.

PRESENTED by the Army Medical Museum, Washington, D.C.

43.61⁴ Atrophy of Spleen with Hyaloseritis.

A small thick spleen, measuring 6.6×4.5×4 cm., the surface of which shows a large area of hyaloseritis (icing), having a raised surface with scalloped edges and outlying small, round, flattened, discrete patches of the same appearance. The rest of the surface is quite rough with adherent lymph. The cut surface shows enlarged

Malpighian bodies. Fibrous trabeculæ cannot be made out. The white colour is due to preliminary hardening in HgCl_2 .

From a white man, aged 72, dying of acute pericarditis. Had had syphilis years before.

P.M. Heart normal; stomach congested; some adhesions about the liver.

Micro. Exam. The fibrous tissue is conspicuously increased; the remainder is very œdematous. The Malpighian bodies are small and rather ill defined. There are numerous pigment-bearing phagocytes in the pulp. The capsule is enormously thickened, fibrillated, and hyaline, with a broad zone of pigment cells separating it from the spleen.

Ref.: E. 1913. A.M.M. 1829.

PRESENTED by the Army Medical Museum, Washington, D.C.

43.61⁵ Senile Atrophy of Spleen.

A small spleen, measuring $7.1 \times 3.4 \times 2.6$ cm. Part of the capsule is missing; the rest is opaque, wrinkled, and portions are conspicuously thickened. There are no notches. The organ is moderately thick. There is no perisplenitis.

The spleen weighed 30 gm.

H. W., male, aged 80, suffered from symptoms of vesical trouble for ten years, due to a papilloma in the bladder.

P.M. Papilloma of bladder, cystotomy; acute cystitis, senile atrophy of all organs; fibrosis of pancreas.

Micro. Exam. Spleen atrophic; trabeculæ prominent. No Malpighian bodies were to be made out.

Ref.: R.V.H. 41.08. E. 3353.

PRESENTED by Dr. Adami.

43.61⁶ Atrophy of Spleen.

An unduly small spleen, measuring $9 \times 7 \times 3$ cm., weighing 65 gm., of reddish colour. There are two notches. The capsule is a little wrinkled. The cut surface is a little congested, with firm pulp, abundant trabecular network and large follicles.

The spleen appears to have shrunk in size, not from senility (the follicles are not atrophic).

S. C., female, aged 65. Admitted to the R.V.H. on Jan. 22,

1913, with gastric pain and diarrhoea and pronounced thirst. She had no children. No family history of cancer. 18,000 white cells per c.mm. Urine contained pus. Vagina full of new growth.

P.M. Carcinoma simplex of cervix (ulcerative form) with local extension; bilateral hydronephrosis; atrophy of organs.

Micro. Exam. The Malpighian bodies are numerous. Many showed necrosis in the centre, and thick hyaline change in the central vessels. The trabeculæ are hyaline. The pulp is rich in fibrous tissue and contains a number of pigmentophages. The vascular channels and pulp ends are very conspicuous, but the number of cells present is small.

Ref. : E. 5402. R.V.H. 9.13.

See Specimen No. 63.79¹.

PRESENTED by Dr. Gruner.

43.61⁷ Senile Atrophy of the Spleen.

A spleen of small size, measuring $8.5 \times 5 \times 2.6$ cm., with sulcus half-way along the posterior border. The edges are rounded, the organ flattened, and the capsule is slightly wrinkled, producing a finely nodular surface. The colour is rather dark, with lighter bands at each end. The cut surface shows a dark pulp rich in trabeculæ. The Malpighian bodies are not easily seen.

Ref. : P.H.I., Verdun. E. 3135a.

PRESENTED by Dr. Kaufmann.

43.61⁸ Atrophy of Spleen.

A small spleen, measuring $7 \times 4.5 \times 2.5$, and weighing 15 gm. There are three notches. The organ is firm, bulky, with a smooth surface. There is a little white calcified nodule of pinhead size near the upper end. The colour is dark red. The trabeculæ are rather conspicuous, and the Malpighian bodies are very minute.

J. D., male, aged 51, was admitted to the R.V.H. Jan. 23, 1913, with obscure symptoms. The existence of adhesions round the gall-bladder was the only definite finding. There was extreme wasting.

P.M. Chronic pericholecystitis; obstruction to the thoracic duct; chronic ulceration of the transverse colon; atrophy of all

the organs; persistent thymus; renal calculus; purpura; enlarged mesenteric glands.

Micro. Exam. The section shows fibrosis. The Malpighian bodies are small, numerous, and contain only lymphoid elements. The central vessels can be clearly seen. The trabeculæ are very conspicuous; the pulp shows a diffuse increase of fibre cells. The blood-channels are everywhere engorged with red blood cells. Numerous pigmentophages are to be seen.

Ref. : E. 5428. R.V.H. 17.13.

PRESENTED by Dr. Gruner.

.62 Degenerations.**.625 Amyloid Degeneration.****43.625¹ Spleen. Early Amyloid Disease of Sago Type.**

The organ is large and tense, pale-coloured with exaggerated notches. Four small white infarcts (two wedge-shaped) occur along the edges, and the cut surface shows mottling with semi-translucent whitish spots which correspond to the Malpighian bodies.

I. N., male, aged 19. A case of hip-joint disease (suppurative arthritis), which had lasted on and off for ten years, following a fall while skating.

Micro. Exam. Recent white infarct. Amyloid disease about the Malpighian corpuscles.

Ref. : R.V.H. 54.07. E. 3392.

PRESENTED by Dr. Adami.

43.625² 'Sago Spleen' in Amyloid Disease.

A slightly enlarged organ with the normal contour preserved. The cut surface is conspicuously mottled from the presence of small, round, semi-translucent areas the size of a pin's head and smaller. They appear dark in contrast to the pale bands which separate them. They correspond in part to the Malpighian bodies.

Ref. : R.V.H. 1896. E. No. 770.

43.625³ Sago Spleen. Amyloid Disease.

Half of a moderately enlarged spleen, measuring 10.5 × 8 cm. The Malpighian bodies are visible as semi-translucent pinhead-sized spots scattered throughout the splenic substance. The intermediate pulp is pale in contrast. The notches are indistinct, but present.

From a woman, aged 28, who died of tuberculosis.

Micro. Exam. The Malpighian bodies are replaced by large rounded masses of hyaline material which shows irregular cleavage, the clefts being occupied by small round cells in small numbers. The centre of each mass shows the remains of the central vessel infiltrated with a few lymphoid elements. At the periphery of each mass is a zone in which there is much dark-brown pigment within

the leucocytes. The spleen-pulp is very rich in cells, many of which contain pigment granules, while very few blood-vessels can be seen. The trabeculæ are rather prominent.

Ref. : St. Bart's. Hosp. E. 3077.

PRESENTED by Dr. Martin.

43.625⁴ Spleen. Amyloid Disease.

A portion of spleen showing well-marked amyloid change (sago spleen). The capsule is not thickened, but is shaggy with firm shreds of lymph. The cut surface shows numerous discrete brownish-coloured nodules of pinhead size or smaller. Each corresponds to a Malpighian follicle. The intermediate pulp is pale. The disease is uniformly distributed.

Ref. : M.G.H. 8.03. E. 1049.

PRESENTED by Dr. McCrae.

.7 PROGRESSIVE CHANGES.**.72 Hypertrophy.****43.72¹ Enlargement of Spleen in Cirrhosis of Liver.**

An enlarged spleen, measuring $14.2 \times 12 \times 6.5$ cm. The surface is opaque over an irregular area, and elsewhere shows fine mottling, with pale spots; the internal surfaces are roughened with recent lymph. There is an accessory spleen at the lower end of the hilum. No notches are seen. The cut surface presents no particular feature.

Old Museum specimen.

PRESENTED by Dr. Howard.

43.72² Spleen. Hypertrophy.

From a coloured child aged 17 days. Died with abdominal cramps.

P.M. Fluid like curdled milk in the stomach, the walls of which were thin and softened, and had two rents. Hypostatic congestion of lungs.

Ref.: A.M.M. 3184.

PRESENTED by Army Medical Museum.

43.72³ Enlargement of Spleen in Cirrhosis of the Liver.

A greatly enlarged spleen, measuring $7 \times 17 \times 0.5$ cm., cut open lengthways. On the outer surface are general short shaggy adhesions, and towards the upper end are several flat, discrete, nodular, ochre-yellow opacities, with a diffuse grey opacity between them. Half-way down the posterior border is a slightly depressed flattened quadrangular area of sclerosed appearance, with one or two ochre-yellow foci visible within it. The cut surface has a uniform grey colour, and shows no differentiation of structure. The texture is very dense, as if there were uniform hypertrophy of the trabecular tissue.

Ref.: E. 4002c.

See also Specimens No. 37.39, 42.361².

PRESENTED by Dr. Klotz.

43.72⁴ Enlarged Spleen in Cirrhosis of Liver. Syphilitic History.

A greatly enlarged spleen, 18×4.5 cm. on the cut surface, having a wrinkled capsule, devoid of abnormalities and with normal notching. The cut surface is bright red with deeper red lining, and shows much increase of fibrous tissue. The Malpighian bodies are readily visible but normal.

J. D., male, aged 54, had syphilis 23 years ago for a year; he also was accustomed to drink spirits heavily. His abdomen was swollen with ascites, and there was jaundice; bile-stained fluid was twice removed by tapping. There was tuberculous peritonitis. There were gummata in the calvarium and cirrhosis of the liver.

Ref.: E. 4103. M.G.H. 10.43.

PRESENTED by Dr. Rhea.

43.72⁵ Hypertrophied and Fibrotic Spleen.

A large spleen, measuring $17.5 \times 11.5 \times 4.8$ cm. and weighing 550 gm. The edges are rounded, the natural shape is preserved, the surface smooth, and the capsule wrinkled. The cut surface is very firm and flat; the trabecular tissue is conspicuous, as also the Malpighian bodies.

L.F., a Chinese male, aged 43, was admitted to the R.V.H. on April 19, 1911, for swelling of the feet and shortness of breath. The case was one of advanced interstitial nephritis. Death occurred from sudden convulsions and coma (uræmia).

P.M. Chronic mixed nephritis with cysts; tuberculous pleurisy; marked œdema of lungs; hypertrophied heart; hydropericardium; ascites; fatty liver; passive congestion of organs; adrenal hyperplasia; anasarca.

Micro. Exam. The capsule is thickened slightly. The trabeculæ are hyaline here and there. The splenic channels are well seen, and there is yellow pigment throughout the pulp.

Ref.: E. 4722a. R.V.H. 58.11.

PRESENTED by Dr. Gruner.

43.72⁶ Movable Giant Spleen. Splenectomy.

Enormously enlarged spleen, measuring $23 \times 12 \times 8$, removed by operation. Weight 1,408 gm.

The organ is very dark in colour, and shows an irregularly bossed surface produced by cicatricial contractions of white colour here and there. A small area of peritoneal adhesions is seen, with a few petechial hæmorrhages in the splenic capsule at their attachment. Just below this, near the middle of the length of the spleen, is a large white infarct projecting considerably above the surface, having a reddish centre on section, and enclosed in a broad zone of deep-red hæmorrhagic infiltration. The cut surface of the spleen is very dark in colour, mottled with hæmorrhages, and showing a decided increase of fibrous tissue.

Female, aged 32, born in Sparta, Greece, and lived there until July 1905 (six months before operation), when she came to Canada. History of malaria fifteen years previously, with attacks occurring at irregular intervals for three years. Pain in the left side set in also about this time and a mass was noticed in the left abdomen, which remained about the same size and gave no further trouble until recently. In August 1905, dragging pain in the left side set in and grew gradually worse. Admitted to Royal Victoria Hospital, October 7, 1905, and had an attack of chills and fever; temperature 104° soon after admission. November 1905 blood-count showed: red cells, 2,500,000; white cells, 4,200; 35% lymphocytes in excess. January 10, 1906: red cells, 3,500,000; white cells, 4,000. Splenectomy was performed January 12, 1906. There were a few peritoneal adhesions. The hilum of the spleen contained very large vessels, and there were large tortuous veins in the adherent omentum. On January 15: red cells, 3,000,000; white cells, 20,000. February 25: white cells, 12,000; Hb, 25%; lymphocytes, 35%. The patient made a good recovery and was still alive in November, 1914.

The size of the spleen on removal was $25 \times 17 \times 11$ cm.

Micro. Examination. Fibroid hyperplasia; swelling and proliferation of endothelial cells of vessels and trabeculæ; lymphocytes relatively decreased; no multinuclear cells seen. Extracellular pigment present. Necrosis of cells and extravasated blood in infarcted area.

Ref.: Surg. 15.06. R.V.H. E. 1141.

PRESENTED by Dr. Garrow.

.78 Sarcoma.**43.78¹ Sarcoma of Spleen.**

Half of a spleen whose substance is occupied by a large spherical mass of tumour which is well encapsuled. The peripheral portions are dark coloured, the central portions show early softening, more or less in radial lines; minute rounded spaces are thus produced. The splenic substance is reduced to a minimal amount, but presents no other abnormality. The capsule is wrinkled.

Ref. : St. Bart's. 68. E. 2301.

PRESENTED by Dr. Martin.

.786 Lymphosarcoma.

43.786¹ Splenomegaly in Generalized Lymphosarcoma of Spleen, Lymphatic Glands, Liver, Kidneys, and Serous Surfaces. Chylous Ascites. Chylous Pleurisy.

An enormously enlarged spleen, measuring $31\frac{1}{2} \times 17 \times 11$ cm. The surface is thickened over large areas in many places: the rest of it is opaque and slightly puckered. There are several areas roughened from perisplenitis. The cut surface shows large nodules of ill-defined new growth infiltrating the pulp, which is so small in bulk as to be almost negligible. Wherever the organ has been cut into the same diffuse infiltration is met with. The edges are round, and there are no notches.

From a man, aged 45. Onset of symptoms several years before death after injury in falling from a street car; four weeks after this accident some swelling in the neck and left side of abdomen was observed, with dragging sensation in the latter region, and some pain and occasional vomiting; a month later suppuration of left inguinal gland necessitating operation, progressive asthenia, and moderate anæmia.

Admitted R.V.H. some two years later with superficial and peribronchial lymph-glands enlarged, spleen much enlarged, liver palpable. Red blood cells, 2,170,000; white cells, 10,000; Hb, 52%; polynuclears and lymphocytes predominating. Two weeks later white cells 32,000, relative increase of large lymphocytes and eosinophiles and a few nucleated reds present.

Readmitted a year later, a few weeks before death. The spleen and glands were now enormously enlarged, the abdomen was much distended, and there was *chylous ascites* and *bilateral chylous pleurisy*, great and progressive asthenia.

P.M. Lymphosarcomatosis of cervical, axillary, inguinal, mediastinal, peribronchial and retroperitoneal glands, pleuræ, peritoneum, spleen, liver, and kidneys. Receptaculum chyli embedded in enlarged glands and dense adhesions. Abdomen and pleuræ full of milky fluid with pinkish tinge. The spleen measured $34 \times 17 \times 11$ cm. and weighed 3,540 gm. The pleuræ and peritoneum were covered with a fine villous growth so closely arranged and so fine in character as to resemble coarse velvet, which consisted, on microscopic examination, of lymphoid cells in a fine reticulum.

See also Specimens Nos. 42.786², 36.786, 37.786.

Ref.: R.V.H. 73.99. Entry No. 566.

Reported *Journ. Med. Research*, 1901, ii. 249-57.

PRESENTED by Drs. Martin and Adami.

43.786² Secondary Lymphosarcoma of Spleen.

A greatly enlarged organ, weighing 630 grm. and measuring $18 \times 10.5 \times 4$ cm. The edges are rounded, and there is no sign of any notch; the surface is mottled with small, round, yellowish-white nodules, some of which are of the size of normal Malpighian bodies, others larger (pinhead size). The larger nodules are foci of new growth. The cut surface shows a generalized diffuse distribution of small, white, closely packed nodules similar to those visible through the capsule.

J. H., female, aged 35. Occupied in heavy field work until January 1895, then began to lose flesh; during the last fortnight before death suffered from complete anorexia and pain in the upper abdomen. On May 4th purpuric patches developed on the forearm, and there was oozing of blood from the gums. On May 5th hæmatemesis occurred, and the purpura was increasing rapidly. Admitted to the R.V.H. May 6th. Petechial hæmorrhages everywhere; teeth loosened and very tender; great thirst; leucocytosis; vomited in all 50 oz. of bloody fluid. Died May 16th.

P.M. Generalized purpura hæmorrhagica. Hæmorrhage into thyroid. Primary sarcoma of cervix uteri. Multiple secondary sarcomata of ovaries, Fallopian tubes, stomach (34.786), peritoneum, spleen, kidneys, liver, lungs, suprarenals, and skin. The spleen was coarsely mottled, deep carmine-red, with firm yellowish areas scattered abundantly throughout the tissue.

Micro. Exam. The spleen showed great over-development of small round cells, along the trabeculæ and along the vessels, evidently lymphosarcoma; and as it was most extensive in the spleen, this, not improbably, was the seat of primary growth. In parts the growth was so extensive that the splenic sinuses were collapsed and bloodless, in others the small round cells could be well seen infiltrating in lines in the splenic stroma. The trabeculæ near the surface were represented by irregularly defined walls or columns of lymphoid tissue, and the same tissue was in parts spread out beneath the capsule. To this subcapsular growth was evidently due the mottled appearance of the surface of the organ. The growth had further invaded the splenic veins; certain sections showing well an infiltration beneath the intima. In parts the endothelium could still be seen covering it in others; the growth had come to project into the lumina.

Ref.: R.V.H. 36.95. Entry No. 1576.

See Drs. Martin and Hamilton, *Journ. Exp. Med.*, vol. i, 1895.

PRESENTED by Drs. Stewart and Adami.

.79 Carcinoma.**43.79¹ Secondary Cancerous Nodule of Spleen.**

A portion of large spleen with well-marked notching of a smooth surface. The capsule is wrinkled. The cut surface shows several large round nodules, 2×7 cm. in diameter; well-defined, but appearing slightly to infiltrate. The cut surface is granular, and shows a faintly radiating appearance.

Micro. Exam. The nodule of tumour is made up of elongated oval acini separated by narrow bands of fibrous tissue. The lumen of the acinus is in many cases swollen out with necrotic cells. The lining is made up of successive layers of spheroidal cells, which break loose from each other as one passes to the centre of the lobule. The tumour is a spheroidal-celled carcinoma of acinous type.

Ref. : E. 4970.

PRESENTED by Dr. Muir, Dissecting Room.

43.79² Secondary Carcinoma of the Spleen.

Two slabs of spleen. The larger measures 40 cm. long and 4 cm. wide, the smaller 17×4 cm. In the larger piece are three large nodules of growth 4, 3.5, and 1.5 cm. in diameter respectively. They are well-defined, subcapsular, and limited above by a thin grey line of pinkish colour. There is a suggestion of whorled arrangement. Besides these, there are seventeen smaller nodules about 0.5 cm. or less in diameter. They have a similar appearance to the larger ones, but show no breaking down in the centre.

The cut surface is not fibrous, and shows few Malpighian bodies. The dark-contoured line 6 mm. from the edge is due to artefact.

The smaller specimen shows eight similar nodules, two of which are subcapsular.

Ref. : E. 4338.

PRESENTED by Prof. W. G. MacCallum.

43.79³ Adenocarcinoma of Spleen (Secondary to Gall-Bladder).

A very small spleen with a rather granular surface mottled with minute grey spots. The surface is generally dark red, and there is one deep incised notch. There are adhesions on the inner side. At the hilum is a small round, brownish-yellow, cloudy, well-defined, fine, homogeneous nodule about 0.6 cm. in diameter. There is a trace of splenic tissue over its surface, so that it is just subcapsular in position. The trabeculæ are prominent and the Malpighian bodies very numerous, distinct, and sand-grain-like.

From a case of obstruction of intestine following kinking by appendicular adhesions.

P.M. Mesenteric glands, large, hard, and appeared caseous in spots. Kidney and coronaries arterio-sclerotic.

Micro. Exam. The nodule is clearly defined and composed of small narrow cleft-like acini of new growth, the lining being formed of very low, almost cubical columnar cells, and they are rather widely separated by structureless fibrous tissue. A broad capsule limits the tumour from the splenic tissue. The spleen capsule is small, as also are the trabeculæ. The arteries in the Malpighian bodies were atheromatous. The tumour tissue is much infiltrated with small round cells.

Ref. : E. 5571.

PRESENTED by Dr. Kaufmann, P.H.I.

.70 Cyst Formation.**43.70¹ Cyst of Spleen.**

A spleen of moderate size (13×7×3 cm., weighing 140 gm.) laid open to show two small cysts near its lower pole (upper in jar). The larger cyst is 1.25 cm. in diameter, completely enclosed by splenic substance, and shows slight loculation of its cavity. The lining is smooth and glistening. Adjacent to it is a smaller cyst which reached the surface, being bounded by a slightly opaque capsule. The cyst walls are glistening, but much more irregular than those of the larger cavity. The contents were clear.

A. H., female Austrian, aged 44. Admitted to the R.V.H. on April 9, 1907, having had symptoms pointing to cancer of the stomach for five months. The condition was found to be inoperable.

P.M. Scirrhus cancer of anterior wall of stomach. No metastases, suppurative peritonitis (streptococcic).

Ref. : E. 3134a. R.V.H. 46.07.

PRESENTED by Dr. Klotz.

43.70² Spleen, Multiple Small Cysts.

Part of a moderately large spleen, showing a number of minute cysts along the border ; the largest measures 4 mm. in diameter, and is well raised above the surface ; it is rounded in shape ; there is no congestion at the border. The walls are translucent. A number of very small cysts occur in the vicinity.

Mrs. E. M., aged 27. Death from cerebral hæmorrhage.

P.M. Cerebral hæmorrhage ; chronic nephritis ; arterio-sclerosis ; chronic myocarditis ; fat-necrosis of liver ; hæmorrhagic pleurisy ; hæmorrhages into skin.

Micro. Exam. The fibrous tissue is moderately abundant. The splenic tissue is apparently normal. A cyst is shown with a lining of a single layer of endothelial cells. It contains coagulated matter and desquamated, highly vacuolated cells. It bears no relation to the ordinary splenic structures.

Ref. E. 4629. M.G.H., A. 10.197.

PRESENTED by Drs. Finley and Curry.

.8 TRAUMATA, OR RESULTS OF TRAUMATA, FROM MECHANICAL, CHEMICAL, OR PHYSICAL CAUSES.

.819 Rupture.

43.819¹ Rupture of Spleen. Splenectomy with Recovery.

A spleen of moderate size which has been torn into two pieces. The larger piece measures $7 \times 8.5 \times 4.3$ cm. ; the smaller $4.6 \times 7.5 \times 3$ cm. ; so that the total organ measured $10.6 \times 8.5 \times 4.3$ cm. A fissure runs along the upper segment parallel to the torn border. There are three contusion marks at the posterior border, and one at the interior. The capsule is tense. The organ is pale, save at the region of the tear, where it is blackened. The lower extremity is quite black, and its capsule is tense. The cut surface of the lower end is very deeply coloured, while the upper one is pale. A portion of deeply congested omentum is mounted beside the organ in the jar.

On Feb. 28, 1912, in the afternoon, a Jewish boy was tobogganing on Fletcher's Field, when he encountered a tree, but failed to jump off and avoid it. He was struck in the side, and lay where he fell for a little while before proceeding home, which was a few hundred yards away. The pain increased so much that a doctor was called in five hours later, and he was removed to the hospital. The operation revealed the tear in the spleen, and that the abdomen was full of blood. The whole organ was removed. The only event was a slight rise in temperature for three weeks, and delayed healing. The patient was alive and well on March 11, 1913.

Micro. Exam. The section through the area of hæmorrhage shows almost entire loss of differentiation owing to infiltration with blood. The parts adjoining show œdematous pulp-tissue and follicles, alternating with irregular and almost discrete focal hæmorrhages. In both cases the effused blood has become a homogeneous, almost structureless, mass.

Ref. : E. 4874. R.V.H. 512.12.

PRESENTED by Dr. Garrow.

431. SPLENIC CAPSULE

CATALOGUE *

.1 ANOMALIES.

None in this series.

.2 CIRCULATORY DISTURBANCES.

None in this series.

.3 INFLAMMATIONS.

.325 Purulent Inflammation.

431.325¹ Suppurative Perisplenitis.

The spleen is small and its surface marked with perisplenitis in large patches of yellowish-grey exudate corresponding to the sites of non-contact with adjoining viscera. The capsule was a little wrinkled. The cut surface is red, the Malpighian bodies small, and the pulp soft.

Mrs. Annie M., aged 44, was admitted to the R.V.H. (March 1911) with symptoms of carcinoma uteri which had existed six months. She had had six children. A panhysterectomy was done.

P.M. Purulent peritonitis, infarct of right lung, perisplenitis, chronic interstitial keratitis. No secondary deposits.

Micro. Exam. Malpighian bodies small and poorly defined. There is desquamation of the endothelium of the splenic channels. The pulp contains many eosinophile cells.

Ref.: R.V.H. 46.11. E. 4684.

PRESENTED by Dr. Adami.

* For abbreviations used in this Catalogue, see p. xviii.

.36 Inflammations due to Acid-fast Bacilli.**.361 Tuberculous Inflammation.****431.361¹ Tuberculosis of Spleen. Involving Capsule.**

A small spleen ($10 \times 6.5 \times 2.5$ cm., weighing 110 gm.), whose surface is intimately adherent with the diaphragm on the one side, and is covered with rather large creamy nodules on the other. These nodules are rounded, slightly lobate, sharply defined, and show no adjacent congestion. The cut surface of the spleen shows its substance riddled with small tubercles which are almost of a size and present slight peripheral congestion. There is little pulp-tissue left. There is no evidence of breaking down within the nodules.

D. R., male, aged 11, was admitted to R.V.H. Sept. 26, 1911, for general weakness. Von Pirquet negative. No tuberculosis in family. Was very emaciated. Glands not enlarged. Abscess in umbilicus. Temperature remittent. Died Dec. 7, 1911.

P.M. Caseous tuberculous peritonitis. Tuberculous perihepatitis, perisplenitis, multiple abscesses in abdomen. Miliary tuberculosis of liver, spleen, and kidney. Accessory spleen.

Micro. Exam. The capsule is much thickened by caseous matter. The pulp is congested. There are caseous areas enclosed in fibrous connective tissue, but no epithelioid cells. The follicles are few in number. A few giant cells occur at the edge of some of the caseous areas. In another section a number of caseating tubercles of large size are present.

Ref. : E. 4785a. R.V.H. 173.11.

PRESENTED by Dr. Gruner.

431.361² Hyaloserisit and Capsular Tubercles of Spleen.

A moderately large spleen whose surface is completely hidden by general adhesions in which are embedded numerous caseating tubercles. The anterior surface shows thickening of the capsule over a large area. The cut surface is dark coloured and homogeneous, and presents but few Malpighian bodies of moderately large size.

From a case of generalized conglomerate tuberculous peritonitis, commencing in the mesenteric lymph-nodes. There was no tuberculosis in the thorax.

There is no microscopic evidence of tuberculosis in the spleen substance proper, except where invaded from the capsule.

Ref. : E. 5475. P.H.I., Ap. 7.13.

PRESENTED by Dr. Kaufmann.

.39 Productive or Proliferative Inflammation.*Chronic Perisplenitis.***431.39¹ Chronic Perisplenitis. Old Adhesions and recent Acute Inflammation.**

The spleen is small, measuring $11.2 \times 5.6 \times 3.8$, and has a very rough surface from old perisplenitis; there is a layer of recent yellow lymph over the anterior surface, and adhesions at the lower end. The cut surface is concave and mottled with pale irregular areas running into each other. The Malpighian bodies are not conspicuous. The consistence was much increased.

Mrs. M., aged 32, was admitted to the R.V.H. December 1910 suffering from a pyosalpinx which had led to pelvic cellulitis and general suppurative peritonitis. She had only had symptoms for two weeks.

P.M. Recent abortion; general peritonitis; enlarged lumbar and mesenteric glands; double salpingitis (gonococcic).

Micro. Exam. The capsule is thickened and the reticulum is conspicuous. The Malpighian bodies are well defined, but the central vessel is hyaline. The channels are dilated and engorged.

Ref.: R.V.H. 176.10. E. 4550b.

PRESENTED by Dr. Adami.

431.39² Chronic Perisplenitis.

The major portion of a moderately large spleen, measuring $11 \times 8 \times 4$ cm. Its surface is concealed by very dense adhesions to the diaphragm. At each extremity the membranous and stringy deposit is transparent enough to enable the splenic capsule to be seen beneath.

The cut surface is mottled with rather large, dark-red, ill-defined areas. There is no increase of the trabecular tissue. The weight was 100 gm., the consistence was hard.

J. S., male, aged 72. Admitted to M.G.H. March 25, 1913, for cancer of the œsophagus. He took alcohol to excess.

P.M. Carcinoma of œsophagus, secondary in larynx, lymph-glands, and liver. Chronic interstitial nephritis. Old perisplenitis. Aortitis.

Micro. Exam. The capsule is much thickened. The fibres of

which it is composed are not laminated, or parallel to the surface of the viscus, but pass out radially. There are but few nuclei present. The splenic pulp is very rich in specific cells.

Ref. : E. 5552. M.G.H. 13.55.

PRESENTED by Drs. Finley and Burgess.

Hyaloserositis.

431.39¹⁰ Spleen with Hyaloserositis.

A moderately enlarged spleen showing an opaque whitish capsule like 'icing' of moderate thickness, without localized thickenings. A line of bright ochre mottling can be seen in one place. The spleen pulp is apparently normal.

J. McG., male, aged 60, was the subject of gonorrhœal stricture and was a hard drinker. He died of cirrhosis of the liver, and had vesical calculi and an enlarged prostate.

Micro. Exam. Concentric layers of fibrous tissue, showing few nuclei. The trabeculæ were prominent and fibroid. The tissue was markedly congested.

Ref. : R.V.H. 115.08. E. 3441.

PRESENTED by Dr. Adami.

431.39¹¹ Hyaloserositis of Spleen.

A spleen of approximately normal size, measuring $11 \times 7.5 \times 4$ cm., whose surface is very much roughened, irregular, and opaque. The lower part of the opaque area in front is quite smooth over a small distance, and has the appearance typical of hyaloserositis. The cut surface shows thickening of the capsule to the extent of 4 mm. There is a reddish-brown colouration of the inner edge, which is slightly scalloped. The pulp is fibrous. Malpighian bodies are hardly visible.

The splenic artery is moderately sclerosed.

C. K., male, aged 76. No clinical notes available. A case of carcinoma of the tongue, associated with well-marked arterio-sclerosis and obsolescent tubercles of the lungs and granular kidney.

Ref. : R.V.H. 68.96. E. 764c.

PRESENTED by Dr. Martin.

431.39¹² Hyaloseritis of Spleen.

A small spleen, 8.5×6.5×3 cm., showing irregular plaque-like thickenings of its capsule, giving it a rough whitish surface. There is a little recent lymph at one pole. The cut surface is dark red and homogeneous. The Malpighian bodies are normal in size and not very distinct. The capsular thickening is only slight, but universal.

Henry P., male, aged 76, was in hospital eight days before death and had been ill a month. He was operated on for hypertrophied prostate. There was chronic interstitial nephritis with large cysts in the kidney. (See Specimen No. 51.39.)

Micro. Exam. The lymphoid tissue was very diffuse. There was some débris of broken-down red blood cells present.

Ref. : R.V.H. 118.07. E. 3103b.

PRESENTED by Dr. Adami.

431.39¹³ Hyaloseritis of Spleen.

A rather small spleen with a very puckered and opaque capsule. The upper two-thirds show a uniform thickening, characteristic of hyaloseritis, which is sharply defined from the remainder, rather yellow over the capsule. Tags of lymph are adherent all over the surface. The cut surface is pale and shows new structure.

Ref. : A.M.M. 2482. E. 1921.

PRESENTED by Army Medical Museum.

431.39¹⁴ Hyaloseritis of Capsule of Spleen.

A small spleen. The capsule is slightly thickened, and is raised in irregular hemispherical plaques almost simulating blisters, having a translucent bluish appearance. Near the border, which is free from notches, the plaques come to be larger and more resemble icing.

F. G., male, aged 21. Death from gangrenous appendicitis with perforation and retroperitoneal suppuration extending up to the diaphragm. Chronic thickening of capsule of right kidney. Localized necrosis of pancreas ; localized peritonitis round wound. Hæmosiderosis of liver.

Ref. : R.V.H. 69.95.

PRESENTED by Drs. Bell and Adami.

*Localized Hyaloseritis. Lamellar Fibroma.***431.39²⁰ Hyaloseritis and Infarct of Spleen.**

A small spleen, measuring $9 \times 6.5 \times 2.5$ cm. The outer surface shows an oblong area of cream-coloured thickening, considerably raised above the surface in some parts. The edges are clearly defined, and are slightly lobated. The capsule is wrinkled. The cut surface is deeply engorged, showing punctate mottling. A wedge-shaped infarct of grey colour is seen. This is marked out by a delicate vivid red line.

T. S., male, aged 85, was admitted to asylum for epilepsy. He died of tuberculous broncho-pneumonia and thrombosis of aorta extending into the iliaes.

Ref. : E. 5304b. P.H.I., Verdun.

PRESENTED by Dr. Sims.

431.39²¹ Lamellar Fibroma of Spleen.

A small spleen, showing a localized area of hyaloseritis, fully 1 cm. in thickness, whose edges are scalloped and project prominently above the general surface of the wrinkled capsule ; it thus has the appearance of icing, and it is of the consistence of cartilage. The cut surface shows some evidence of lamination and is semi-translucent. The capsule can be seen to be continued beneath it. The spleen-pulp is fibrous and Malpighian bodies are normal.

G. R., male, aged 43. Cough with profuse expectoration, weakness and loss of appetite set in in the end of March 1907. The patient became much emaciated and died May 11, 1907.

P.M. Acute broncho-pneumonia ; bronchiectasis ; chronic nephritis, pleuritis, and pericarditis ; chronic perisplenitis.

Ref. : M.G.H., A. 07.87. E. 3022.

PRESENTED by Dr. Duval.

431.39²² Hyaloseritis of Capsule of Spleen. Lamellar Fibroma.

A very small spleen laid open. The capsule is everywhere thickened, but near the hilum is a localized hard mass, 1.2 cm. thick, of translucent pink colour, laminated structure, and cartilaginous hardness. The outer surface is regular in outline, the inner is irregularly scalloped. This portion corresponds to the 'lamellar fibroma'. The spleen-pulp itself shows no abnormality.

Mrs. M. M., aged 48. Died within 20 minutes of admission to the hospital. She had been ill for two years with weakness, shortness of breath, palpitation of the heart, and extreme anasarca.

P.M. Obliterative pleurisy, 'icing' under lower lobe of each lung, adherent pericardium, ascites; shortening and thickening of the omentum, parietal peritoneum, and liver. Duodenal ulcer; sclerosis of renal, mesenteric, and other abdominal arteries.

Micro. Exam. The spleen is atrophied, the trabeculae being relatively more numerous than usual; the capsule is irregularly thickened and covered with tags of old adhesions. The thickening of the capsule is due to a proliferation of the fibrous tissue, but is more cellular than in the case of the pleura and the Glisson's capsule. The Malpighian bodies and spleen-pulp show no abnormality. In the blood-vessels are great numbers of organisms, but the pulp is free.

Agar-cultures gave a bacillus of the colon group.

Ref.: R.V.H. 'On a Somewhat Rare Form of Chronic Inflammation of the Serous Membranes (Multiple Progressive Hyaloseritis),' by A. G. Nicholls, M.A., M.D., R.V.H. *Bulletin*, vol. i, No. 3. E. 43. See also Specimen No. 25.39.

PRESENTED by Drs. Hamilton and Nicholls.

431.39²³ Localized Hyaloseritis of Capsule of Spleen.

A small spleen (10.4 × 6.2 × 2.8 cm.), showing two-thirds of its surface covered by a thick cartilaginous 'icing' of absolutely smooth surface, and slightly lobate contour. There are a few deep, round, punched-out holes here and there. The remainder of the surface of the spleen shows no change. The capsule is very tense. The cut surface is rather dark and quite homogeneous. The Malpighian bodies are not visible, and the trabecular tissue is not increased. The inner surface of the capsule at the thickened part is perfectly smooth and clearly defined from the splenic tissue.

J. S., male, aged 72. Admitted to M.G.H. from P.H.I., Verdun, Dec. 29, 1908, with a hard irregular tumour on right side of neck behind angle of jaw, extending from the mastoid to mid-line of neck, fixed to deep structures. No other glandular enlargement. History of onset of swelling five months previous. Died under operation for removal of glandular swelling Jan. 5, 1909.

P.M. Chronic pericarditis, myocarditis, endocarditis, nephritis, bronchitis, hepatitis, and pancreatitis; broncho-pneumonia, calculus of common duct, hyaloseritis of liver and spleen.

The spleen weighed 175 grm., capsule white and of cartilaginous consistency, and about 0.5 cm. thick, except over small area at each pole. Pulp dark red and friable. Malpighian bodies and trabeculæ poorly distinguished.

Ref.: E. 4821. M.G.H., A. 09.3.

PRESENTED by Dr. Rhea.

.70 Cyst Formation.**431.70¹ Cysts of Splenic Capsule.**

Spleen, measuring $9.7 \times 1.7 \times 2$ cm., shows collections of small cysts along the anterior border for a length of 5 cm., and a breadth of 1.2 cm. in the widest part. They are capsular. There is no other noteworthy point in the organ.

Mrs. M. S., aged 44, was admitted to the R.V.H. July 2, 1913, for a large chronic callous gastric ulcer. The clinical history has no bearing on this specimen.

P.M. Chronic callous gastric ulcer with erosion of blood-vessel and death from hæmorrhage; acute necrosis of liver; cavitation of adrenal; granular kidneys.

Micro. Exam. The cysts are dilatations of the lymphatics; they are lined by flat endothelium and contain slightly coagulable material. The pulp-tissue is very loose. The Malpighian bodies are very small.

Ref. : E. 5610. R.V.H., S. 107.13.

PRESENTED by Dr. Gruner.

.7 PROGRESSIVE CHANGES.**.79 Malignant Tumours. Carcinoma.****.796 Adenocarcinoma.****431.796¹ Peritoneal Cancer of Spleen.**

A portion of spleen, a large part of the surface of which shows moderate thickening, of pinkish colour and irregular outline. On the cut surface the thickening is seen to be 2 mm. deep and resting upon a normal capsule. The spleen-pulp is dark in colour, and the Malpighian bodies are normal; no evidence of fibrosis. The surface is roughened here and there in parts other than the diseased area by tags of lymph. (Contrast with this the appearance of hyaloseritis in Specimens No. 431.39¹⁰⁻²³.)

G. M., male, aged 19. Abdominal pain began in July 1909, six months before death, and abdominal swelling was noticed a little later with some epistaxis and hæmaturia. On Oct. 4th 194 oz. of fluid were removed from the abdomen by paracentesis. An irregular nodular mass in the upper quadrant was then made out, and a large mass was also detected in the rectum. Paracentesis of the abdomen was performed again on Oct. 12th. Died Dec. 25, 1909.

P.M. Cancer of transverse colon with extension into great omentum and metastases into parietal peritoneum, diaphragm, pleura, abdominal, pelvic and thoracic glands, liver, adrenals, and left ureter. Caseous tuberculosis of left lung.

This was an unusual case of cancer of the transverse colon with remarkable cancer *en cuirasse* of the parietal peritoneum, simulating chronic hyaloseritis.

Micro. Exam. There was no secondary cancer within the organ, but the surface formed thick layers of growth composed of adenomatous masses in a relatively abundant fibrous stroma. The alveoli were sharply defined, and gave the impression of having a distinct basement membrane on which was placed a layer of cells, sometimes one, sometimes two or three cells in thickness, the cells being elongate or irregularly columnar. These alveoli had a moderately long lumen containing cell debris.

Ref. : R.V.H. 140.09. E. 4048.

PRESENTED by Dr. Adami.

44. THYMUS GLAND

INTRODUCTION

Anatomy. A two-lobed organ situate partly in the thorax and partly in the neck. It arises in the same manner as the tonsil, from a thickening of the hypoblast in the third cleft recess. The thickened area pouches out and undergoes subdivision into small buds or acini. Lymphoid cells come to be associated with these buds, and the supporting tissue is derived from the surrounding mesoblast. Two lateral lobes are completely separated off from the original single mass. They come together anteriorly and below, while their upper ends are found to pass under the thyroid at the time of birth. The maximum development of the organ is attained by the end of the second year, after which time it gradually diminishes in size, undergoing a replacement of lymphoid by fat cells.

Histologically, the thymus is found to consist of a cortical and a medullary portion, broken up into polygonal lobes by narrow bands of connective tissue. The whole is enclosed in a firm fibrous capsule. The gland-substance proper is composed of lymphoid cells, which possess very intensely staining nuclei. The cells of the cortical portion differ somewhat in appearance from those of the medullary portion. There is some evidence for believing that these cells are not true lymphocytes.

Scattered amongst the lymphoid cells are small nests of epithelial cells, known as Hassall corpuscles. These are considered to be relics of the gill-cleft epithelium. Some authors have regarded their relation to the production of the lymphoid cells around as being very intimate.

Physiology. The gland is generally believed to be a blood-forming organ, of great importance for foetal life and early childhood. The fact that its presence bears a definite relation to the development of the body as a whole, points to the suggestion that its real function is of far-reaching importance. At the present time, the student should preserve an open mind about this question.

The Museum Collection. Almost the only feature of pathological interest that can be exhibited in a museum preparation of the thymus gland refers to the existence of *variations in size* at different ages. The anatomist, as above mentioned, regards the maximum

size to be attained at the age of 2 years. Our series shows that the bulk of the thymus may be considerable even at the age of 17 (44.72³). Even up to the years of 30 or 60 quite a large gland may be found, in the experience of autopsy work.

The average size natural to the new-born child is shown in the anatomical specimen 44¹.

Enlargement of the gland in association with increased lymphoid tissue throughout the body (so-called status lymphaticus), is exemplified by 42.526^{1,2}.

The only other feature of pathological interest illustrated in this series is the occurrence of *sarcomatous* development in the thymus. The specimen 42.786¹ affords a very good example of a case in which the thymus has undergone lymphosarcomatous change and grown upwards into the neck and towards the axilla, producing a very large mass with the clinical features of Hodgkin's disease. Such a change is usually aptly described for clinical purposes as 'mediastinal tumour', and the student is advised to consult the section of mediastinal tumours for comparison with this particular specimen (01.78).

O. C. G.

DETAILED TABLE OF CONTENTS

44. THYMUS GLAND

Ages, Size at different :

Birth	44.72 ¹ .
1 year	44.526 ² .
7 years	44.72 ⁴ .
17 years	44.72 ² .
35 years	44.72 ³ .
Hypertrophy of	44.72 ¹⁻⁵ .
Lymphosarcoma of	42.786 ¹ .
? Persistent, quoted in	41.71 ⁷ ; 43.61 ⁸ .
Status lymphaticus, Thymus in	44.526 ^{1,2} .
Tuberculosis, Thymus in	44.526 ¹ ; 44.72 ³ .
Typhoid, Thymus in	44.72 ⁴ .

44. THYMUS GLAND

CATALOGUE *

.1 ANOMALIES.

See under 44.526.

.2 CIRCULATORY DISTURBANCES.

None in this series.

.3 INFLAMMATIONS.

None in this series.

.4 INFECTIONS.

None in this series.

* For abbreviations used in this Catalogue, see foot of page xviii.

.5 GENERAL OR CONSTITUTIONAL DISEASES.**.52 Diseases of Ductless Glands.****.526 Status Lymphaticus.****44.526¹ Thymus Gland, Enlargement at 14 Months in Status Lymphaticus.**

Heart of child with thymus *in situ* above it. The gland is about the same size as the heart itself, measuring 4×5 cm. It has two distinct lobes.

E. V., female, aged 14 months. The child was well developed but anæmic, with enlarged tuberculous cervical glands. Died on the table during operation for removal of the glands.

P.M. Tuberculosis of cervical glands; hyperplasia of mesenteric glands and of thymus.

Ref. : R.V.H. 72.98. Entry No. 653.

PRESENTED by Dr. Adami.

44.526² Thymus, Tonsils, Lymphoid Elements of Intestine and Mesenteric Glands in Status Lymphaticus.

The tonsils are about the size of the thumb, and the papillæ circumvallatæ at the base of the tongue are very prominent. The thymus (mounted just below) is enlarged, about the size normal in a child of 1 year, measuring 9×4 cm. The mesenteric glands (below) vary in size from a pea to a marble. There is a long strip of small intestine in the jar, and throughout its whole length the solitary follicles and Peyer's patches are much enlarged.

F. C., male, aged 7. Sudden death after compound fracture of right tibia and fibula.

P.M. All the lymphatic structures were hypertrophied.

Ref. : R.V.H. 149.03. Entry No. 948.

PRESENTED by Dr. McCrae.

.7 PROGRESSIVE CHANGES.**.72 Hypertrophy.****44.72¹ Thymus. Enlargement at Birth.**

The specimen consists of neck and thoracic organs, showing a bilobed thymus of large size. The lobes are flat and leaf-like, and have a larger surface area than the heart.

The thyroid is also enlarged.

Infant K., new-born, male; case of status lymphaticus.

P.M. Showed the thymus enlarged so much as to encroach upon the greater part of the pleural cavities. The mesenteric glands were not enlarged. There was a fat deposit beneath the pleura (see Specimen No. 25.622¹). There was also a hypospadias (see Specimen No. 58.1).

Ref. : Mat. 81.08. Entry No. 3113.

PRESENTED by Dr. Klotz.

44.72² Thymus at 17 Years.

The gland consists of two long, flat, narrow lobes, each measuring 10×2 cm. at the widest part.

R. L., male, aged 17. Death was due to severe scalding by falling into a tank of boiling water.

P.M. Enlarged pelvic and abdominal lymph-glands and spleen; hydrothorax.

Ref. : R.V.H. 121.04. Entry No. 1286.

PRESENTED by Dr. Klotz.

44.72³ Thymus in Adult.

The specimen shows a bilobed thymus attached to the larynx. Each lobe of the thymus measures 4×1.5 cm. The lobes are well formed and their lower extremities thick.

From a married woman, aged 35, admitted to this hospital Sept. 24, 1904, for tuberculous stricture of the rectum. There was tuberculosis also of the ileum and colon. The spleen was lardaceous.

The specimen is of interest because it shows how large the thymus may be in an adult.

Ref. : E. 1425. R.V.H. 134.04.

PRESENTED by Dr. Klotz.

44.72⁴ Thymus in a Child of 7 Years.

The specimen consists of the thoracic viscera of a child, dissected to show a flat leaf-like thymus, in which there are indications of the two lobes. It measures 5.5×1.5 cm. The cut surface of the gland shows the typical fawn-coloured homogeneous appearance of active tissue.

From a boy aged $7\frac{1}{2}$, dying of typhoid fever with perforation. There was a history of three days' illness before admission, and death occurred on the 22nd day. The symptoms were of the toxic type.

P.M. Typhoid ulceration of the intestine with perforation; proliferative plastic pelvic peritonitis; caseous tuberculosis of the glands; ulceration of the transverse colon.

Ref.: E. 4365a. R.V.H. 116.10.

PRESENTED by Dr. Gruner.

44.72⁵ Enlargement of Thymus and Hyperplasia of Cervical Lymph-nodes.

The specimen shows a cluster of enlarged glands with a lobulated surface and slightly mottled with congestion. They are only partly discrete.

The larynx, tonsils, tongue, and upper end of the œsophagus are mounted with the glands to show the upper circle of enlarged lymphoid follicles about the rest of the tongue.

H. H., female, aged 3 years. Admitted to the M.G.H. on Feb. 18th suffering from burns. Died two hours after admission.

P.M. Enlarged thymus and tonsils, burns of upper and lower extremities (first and second degree). General lymphoid hyperplasia. E. 4803. M.G.H., A. 11.10.

PRESENTED by Dr. Rhea.

.78 Sarcoma.**.786 Lymphosarcoma.****42.786¹ Lymphosarcoma of Thymus.**

A large mass of tumour of irregular form. The lower end is thin and of the shape of the lobes of the thymus gland. From this situation it passes upwards, enveloping the trachea, œsophagus, and main vessels of the neck. The mass is more bulky on the left side, where it forms lobulated masses corresponding to individual glands. These are very closely adherent to each other. The portions of tumour between these and the main growth are ossifying and contain numerous sharp spicules in their substance. The bulk of the mass includes the bronchial glands and all the tissues around the hilum of the left lung.

At autopsy the tumour was found to be growing directly into the dorsal vertebral column and spinal canal, spreading out in the form of a flattened mass between the dura and the bone for the distance of 3.5 cm. The main air-trunks were very firmly enveloped.

N. J., male, aged 27, was admitted to R.V.H. July 3, 1911, for enlargement of the glands of the neck and axilla; this had lasted for two years. The condition began as a small tumour, the size of a marble, on the left side of the neck just above the clavicle. It gradually enlarged on both sides of the neck up to behind the ear. Six months ago, the axillary glands began to swell. A week before admission one of the nodules was removed, and was said to be not tuberculous. Two weeks before admission, he noticed numbness in the legs, commencing in the big toe and reaching up to the knees. The legs were weak and stiff. For eight weeks he had been having X-ray treatment, as well as arsenic, which caused the glands to considerably diminish in size. Four months ago pain developed in the left elbow and in the back about the third and fourth dorsal vertebræ. It was worse at night.

On admission the blood-count gauged: reds, 5,320,000; whites, 5,470; Hb, 72%. The glands were removed on each side of the neck; tenderness was noted over the fourth dorsal spine; increased knee-jerks on both sides.

Nov. 3rd: Polynuclears 69, transitionals 5, large mononuclears 12, small mononuclears 13, eosinophiles 1. Oct. 6th: Hard mass of glands like stone above the left clavicle. Axillary glands on left side shotty. Dullness over sternum and other costal spaces, also between the scapulæ. Left limb almost completely paralysed. Nov. 19th: High temperature with delirium. Loss of sensation in legs and back. *Diagnosis*: Hodgkin's disease, with metastases in spinal cord, intradural, with pressure on cord.

P.M. Lymphosarcomatosis of superior mediastinum and cervical, axillary, and lumbar glands. Invasion of dorsal spine, enlarged lymph follicles of duodenum, enlarged diffuent spleen, red diffuent bone-marrow, obsolescent apical phthisis, hypostatic pneumonia, multiple bed-sores.

Micro. Exam. The first noteworthy feature is the variable character of the changes. Some glands present excessive fibrosis of the capsule and inter-trabecular tissue as the sole lesion, apart from the necessarily induced atrophy of the original follicles. There is here no intimation of cells of abnormal type, no eosinophilia, and no obvious endothelial proliferation. Other glands, however, present characters which pass very well for those labelled 'Hodgkin's disease'—that is to say, endothelial hyperplasia with marked local eosinophilia and appearance of cells of giant size. Other glands again show a great preponderance of the giant cells which give a very characteristic appearance to the section. These giant cells, and the heterogeneous medley of small uninucleate cells of different form show that we have before us something quite different from what we conceive to be the character of Hodgkin's disease, which, as the trend of modern study goes to show, is an infective granuloma of unknown causation. The present case is granulomatous in character, but very atypical, and is distinguishable by the suffix 'sarcoma'.

A brief review of the cell types found in Hodgkin's disease as contrasted with those found in the present case may be found useful. In Hodgkin's we have (1) *Small lymphocytes*, which tend to diminish in number as the disease progresses, besides showing degenerative changes in shrinkage of nucleus and fragmentation of the nucleus into sickle-shaped or spherical particles. (2) *Plasma cells*, which have been derived from some of the lymphocytes; frequently we can see fusion of these cells into miniature plasmoidal masses containing two or three nuclei. Such cells are quite characteristic in the present case, constituting one of the varieties of giant cells seen, and are associated with small clusters of plasma cells, so that here we have scattered small plasmomata. That such tumours can arise in lymphatic glands has been demonstrated from a study of many of the ordinary lymphatic glands met with at autopsy here in the R.V.H. (3) *Mast-cells* occur in small numbers, especially near the capsule. (4) *Reticular cells*. (5) *Endothelial cells*. (6) *Connective-tissue cells*. These three last-named types of cells undergo marked proliferation, and come to be so similar in appearance and so inextricably intermingled that it is difficult to pick out the different forms from one another. Without going into the cytological details which will enable the differentiation to be made, we may point out the presence in this case of the epithelioid cells which are derived from the endothelial cells (5), and which appear as very large cells with solitary nucleus. These are very conspicuous also in Hodgkin's disease, but especially so here. Many of these cells show active but atypical mitosis, so that many examples of multinucleate cells, otherwise conforming to this type, are met with. These cells are entirely different from the epithelioid

cells met with in tuberculous granulomata, as shown by the intensely staining chromosomes, the wide interval between the separated clumps of chromatic material, and the close resemblance to the basket-nucleus-bearing megakaryocyte of the bone-marrow. Not a few of these cells in the case under consideration present characters like those shown by the bone-marrow.

As regards the connective-tissue cells (cell-type 6), we find these definitely increased in certain areas, as would be expected to occur as a replacement process in tissue which has become abnormal; however, it cannot be doubted that we have here an active process by which these fibroblastic cells are actually invading the diseased tissues. The questions arise whether these cells are derived from the adventitia of the vessels of the lymph-gland (or thymus), and whether they play any part in the appearance of some of the abnormal mononuclear elements characteristic of these tissues.

(7) *Neutrophile leucocytes* are few. (8) *Eosinophiles* form perhaps the most striking feature, and we here come upon the hotbed of discussion as to the significance of these cells in a tissue where there is no associated blood-eosinophilia. This discussion we do not propose to enter into here, but merely point out that the cells are so closely clustered along the trabeculæ, and along the zones of fibroblastic hyperplasia, that they may be looked on as related to the *position* of whatever *abnormal (toxic) substance* is present in the foci of unduly active cell-proliferation. The association of eosinophiles with the normal intestinal mucosa where there is constant absorption of breaking-down products of proteid digestion seems profoundly suggestive of this view. (9) *Russell bodies*, and *Charcot-Leyden crystals*. These were not noted in the present case. (10) *Necrotic areas*. These also were conspicuously absent in the present case.

PRINTED IN ENGLAND
AT THE UNIVERSITY PRESS, OXFORD

MP
M

359102

McGill University. Medical Museum
Descriptive catalogue of the Medical Museum...
ed. by M.E. Abbott. pt. IV, sec. 1.

**University of Toronto
Library**

**DO NOT
REMOVE
THE
CARD
FROM
THIS
POCKET**

Acme Library Card Pocket
LOWE-MARTIN CO. LIMITED

